

**Reliability of ultrasound imaging measures of soft tissue stiffness using elastography in the posterior aspect of the leg**

---

**Maria Paula Toledo**





## Library form

**Full name of author:** Maria Paula Toledo

**Full title of thesis:** *Reliability of ultrasound imaging of soft tissue stiffness using elastography in the posterior aspect of the leg.*

**Department of** Osteopathy

**Degree:** Masters of Osteopathy **Year of presentation:** 2016

I agree to my thesis being lodged in the Unitec Library (including being available for inter-library loan), provided that due acknowledgement of its use is made. I consent to copies being made in accordance with the Copyright Act 1994.

**and**

I agree that a digital copy may be kept by the Library and uploaded to the institutional repository and be viewable worldwide.



## Declaration

**Name of candidate: Maria Paula Toledo**

This Thesis entitled: *Reliability of ultrasound imaging of soft tissue stiffness using elastography in the posterior aspect of the leg* is submitted in partial fulfilment for the requirements for the Unitec degree of Master of Osteopathy.

### CANDIDATE'S DECLARATION

I confirm that:

- This thesis represents my own work;
- The contribution of supervisors and others to this work was consistent with the Unitec Regulations and Policies.
- Research for this work has been conducted in accordance with the Unitec Research Ethics Committee Policy and Procedures, and has fulfilled any requirements set for this project by the Unitec Research Ethics Committee.

Research Ethics Committee Approval Number: 2015-1003

Candidate Signature: .....Date: .....

Student number: 1416571

# Acknowledgements

I would like to give my sincere thanks to the people who have supported me and helped make this achievement possible.

Thank you to my supervisor, Robert Moran, for your patience, assistance and expertise throughout this process.

Thank you to all the participants for their willingness and time.

Thank you to Sound Experience Ltd and Scott Allen for giving access to equipment and for your time.

A special thank you to my very best friend and fiancée Alastair, for walking this journey next to me and for always being there for me. We've achieved this together, and now we are starting a more exciting project together, parenthood to our little Emilia.

Another especially thank you to my amazing mum, Laura, for always believing in me and inspiring me to go through with all my aspirations. For all the emotional support through this process and for always encouraging me even though I'm in the other side of the world.

Thank you to all my Argentinian and kiwi family and friends for all the love, continuous support and encouragement you have given me.



# Table of Contents

Library form .....	3
Declaration .....	4
Acknowledgements .....	5
Table of Contents.....	7
SECTION I – Literature Review .....	10
INTRODUCTION .....	12
Lower leg injuries and dysfunctions. ....	13
<b>PART A</b> .....	15
1. SOFT TISSUE STIFFNESS DEFINITION .....	15
Implications of abnormal tissue stiffness in the human body.....	16
2. STIFFNESS IN THE MUSCULOSKELETAL FIELD .....	16
Clinical implications for muscle stiffness.....	16
Tendon stiffness functional and clinical implications. ....	18
Clinical consequences of fascial stiffness .....	18
3. DIFFERENT ELASTOGRAPHY METHODS.....	19
Magnetic resonance elastography.....	20
Advantages and disadvantages of magnetic resonance elastography.....	21
Ultrasound elastography. ....	21
Advantages and disadvantages of ultrasound elastography.....	22
4. ULTRASOUND ELASTOGRAPHY TECHNIQUES .....	22
4.1 Strain elastography.....	23
4.2 Shear-wave ultrasound elastography.....	23
4.3 Transient ultrasound elastography.....	24
4.4 Acoustic radiation force impulse.....	25
5. METHODS OF ELASTOGRAM INTERPRETATION AND ANALYSIS.....	26
5.1 Qualitative method.....	27
Visual grading system.....	27
5.2 Semi-quantitative methods.....	27
5.2.1 <i>Histogram of pixel distribution</i> .....	27
5.2.2 Strain-ratio.....	28

5.3	Quantitative method.....	28
	Elastography summary.....	29
6.	APPLICATION OF ULTRASOUND ELASTOGRAPHY IN MUSCULOSKELETAL STRUCTURES .....	29
	Introduction.....	29
6.1	Usefulness of UES in characterising normal and abnormal soft tissue stiffness.....	30
6.2	Stiffness in muscle activation during fatigue and/or pain.....	30
6.3	Muscle stiffness through life-span and by sex.....	31
6.4	Ultrasound elastography for diagnosing varied musculoskeletal dysfunctions and pathologies.....	31
6.5	Ultrasound elastography for the assessment of treatment and rehabilitation outcomes.....	32
	Rehabilitative ultrasound imaging .....	33
7.	THE LOWER LEG .....	35
7.1	Anatomy of the posterior aspect of the lower leg.....	35
7.2	Injury, pathology and dysfunction of the lower leg.....	37
<b>PART B</b>	.....	39
	RELIABILITY OF UES ON LEG STRUCTURES .....	39
	Search method.....	39
	Search results.....	40
	Quality assessment.....	45
	Methodological issues identified in the studies reviewed.....	45
	<i>Intra-rater</i> reliability.....	48
	<i>Inter-rater</i> reliability.....	49
	Recommendations for future studies.....	49
	REFERENCES.....	51
SECTION II – Manuscript	.....	68
ABSTRACT	.....	70
INTRODUCTION	.....	72
METHOD	.....	74
	Design.....	74
	Participants.....	74
	Examiners.....	74

Procedures.....	75
Extraction and processing of images.....	78
Data Analysis.....	80
RESULTS .....	81
<i>Intra</i> -operator.....	81
<i>Inter</i> –operator.....	81
DISCUSSION .....	86
REFERENCES .....	90
SECTION III – Appendices .....	96
Appendix 1- Ethics documentation.....	97

## SECTION I – Literature Review



## INTRODUCTION

In both general medicine and amongst manual and manipulative therapies, the assessment of the elastic properties of soft tissues has important clinical implications within the diagnostic and treatment process. In clinical practice one of the most assessed soft tissue properties using manual palpation is change in tissue texture (Ward, 2002). Tissue texture changes can often be noted through palpation and felt as stiffness. Altered tissue texture, like stiffness, is thought to be present in muscles with increased tone, in congestion of tissues and may be associated with dysfunction or pathology of the involved soft tissue (Sammut & Searle-Barnes, 1998). Hence the evaluation of soft tissue stiffness has essential clinical value.

Traditionally, the assessment of tissue texture has been performed using manual palpation. However, the use of palpation has several inherent limitations. The accuracy, depth and objectivity of manual palpation for detecting tissue texture changes has been challenged (Comeaux, Eland, Chila, Pheley, & Tate, 2001; Comeaux, 2001; Haneline & Young, 2009), and there is a need for more objective methods of soft tissue assessment.

Elastography is a medical imaging technique used to map information about the stiffness of soft tissues (Sarvazyan et al., 2011). This technique has opened new opportunities to evaluate deeper tissues that cannot be reached through palpation. Elastography imaging methods are now widely available in common commercial imaging applications. In general medicine, ultrasound elastography is being widely applied to diagnose the presence of stiff masses in certain organs, including the prostate (G. Xu et al., 2014; Zhang et al., 2014), breast (Xydeas et al., 2005; Zhu et al., 2008), breast (Gong et al., 2011; B. Liu et al., 2015) and liver (Fraquelli et al., 2007; Jeong, Lim, Lee, Jo, & Kim, 2014).

In recent years the use of elastography in general in the musculoskeletal field has gained popularity in both research and clinical applications (Barr, 2012; Lalitha, Reddy, & Reddy, 2011). In general terms, elastography in all its forms has been useful for the assessment of skeletal muscle pathologies including myopathies (Botar-jid, Damian, Dudea, Vasilescu, & Rednic, 2010) and spasticity (Kesikburun et al., 2015). Quantifying the viscoelastic

properties of skeletal muscle may help improve understanding of the functional and biomechanical behaviour of muscles. For example, muscular compensation strategies when fatiguing a synergist muscles have been investigated with elastography (Bouillard, Jubeau, Nordez, & Hug, 2014). Additionally, the stiffness of muscle have been assessed under load and/or under various joint positions, providing important information of both muscle function and elastic properties (Chino, Akagi, Dohi, Fukashiro, & Takahashi, 2012). Understanding the biomechanical behaviour of skeletal muscle has application in several fields, including orthopaedics, sports medicine, and general rehabilitation.

Research using elastography has been conducted to assess treatment and rehabilitation effects in myofascial structures (Akagi & Takahashi, 2013; Kubo, Kanehisa, & Fukunaga, 2002; Luomala, Pihlman, Heiskanen, & Stecco, 2014). For example, Akagi and Takahashi (2013) investigated the immediate effect of static stretching on muscle stiffness of the gastrocnemius. Other examples of application of elastography in rehabilitation include, Luomala et al. (2014) who identified changes in stiffness of deep leg fascia after the application of a manual therapy technique, and Eriksson Crommert, Lacourpaille, Heales, Tucker, & Hug (2015) who reported an immediate reduction in muscle stiffness after massage. Despite its use in the musculoskeletal field, there is little information regarding the reliability of elastography in musculoskeletal applications.

The topic of this thesis is reliability of elastography based measures of calf muscle stiffness, however, throughout the literature a range of largely synonymous terms have been used to represent stiffness, including ‘tightness’, ‘hardness’, and ‘elasticity’. For the purpose of this review and to ease reader burden the term ‘stiffness’ will be used.

### Lower leg injury and dysfunction

In the lower leg, dysfunction and injury are common in both athletes and non-athletes (Campbell, 2009; Jan Ekstrand, Martin Häggglund, & Markus Waldén, 2011; van Gent et al., 2007), with the most frequent injuries being calf tears and strains (Mueller-Wohlfahrt et al., 2013). Altered mechanical properties of the skeletal muscles of the calf area, such as abnormal stiffness, can lead to dysfunctional repercussions in surrounding lower limb joints (such as knee and ankle) (Cohen, 2009; DiGiovanni, Kuo, Tejwani, Price, Hansen Jr., et al.,

2002; McKay, Goldie, Payne, & Oakes, 2001) and can predispose to further injuries and pathologies such as ankle sprain (Neely, 1998), muscle strain (Mahieu, Witvrouw, Stevens, Van Tiggelen, & Roget, 2006) and tendinopathies (Backman & Danielson, 2011). The apparent link between altered skeletal muscle stiffness and dysfunction/ injury highlight the importance of a valid and reliable tissue stiffness assessment method.

This literature review is divided in two, Part A and Part B. Part A is a narrative review of the background literature around the topic of elastography and its application in musculoskeletal structures.

Part A commences with a general overview and definition of soft tissue stiffness and its importance in health generally, and more specifically in the musculoskeletal field. A description of the different elastography methods (including magnetic resonance imaging based elastography, and ultrasound based elastography) with their main application, advantages and disadvantages will also be covered. Special focus will be given to ultrasound elastography, including its main use, the basic principles of these techniques, and the strengths and limitations of its measurement capabilities. The review will also describe the different forms of analysis and interpretation of ultrasound elastograms. Finally, the review will conclude with a brief overview of the anatomy of the lower leg and the most common injuries that affect this region and their links to stiffness.

Part B will be a more focused critical appraisal of studies investigating the reliability of ultrasound elastography assessing lower leg musculoskeletal structures. It will commence with describing the search strategy employed to identify and select the studies appraised. This is followed by a focused critical appraisal of the methodological quality of the selected papers before making recommendations for future studies that provide a basis for undertaking the investigation reported in Section 2 of this thesis.

## **PART A**

### 1. SOFT TISSUE STIFFNESS DEFINITION

While the elastic properties of structural materials have been extensively characterized by engineers and physicists, these properties are less well known for biological soft tissues. The scarcity of such data in the literature most likely originates from the technical difficulties for measuring these elastic properties of semi-solid biologic tissues in conventional laboratory tests. In engineering, the term ‘stiffness’ is used to describe the force required to achieve a certain deformation of a mechanical structure (Baumgart, 2000). Stiffness is also defined as the change in tension per unit change in length (Calancie & Stein, 1987). This means that when applying tension through an object, it will be elongated in relation to the force. The structure’s ability to resist deformation when a force (or stress) is applied to it, is known as Young’s modulus (Askeland & Fulay, 2005). The units of measurement for Young’s modulus is one of pressure, therefore the *Système Internationale* unit is Pascals (Pa) or, in the United States, pounds per square inch (PSI).

The viscoelastic properties of soft tissue depend on both the molecular building blocks, and the microscopic and macroscopic structural make up (Fung, 2013). Most soft tissues have stiffness properties that are intermediate between those of fluids and solids, which relate largely to their viscoelastic properties. Different tissues are expected to respond differently according to the specific elastic modulus. If a soft tissue is subjected to increasing tension, its extensibility will reach its ‘elastic limit’. Beyond the elastic limit, the material will break or fail to fully recoil. This is particularly true for connective tissue, both in trauma and in therapeutic applications such as manual therapy (Chaitow, 1997).

In the clinical practice of manual therapy, the term ‘stiffness’ is often used by practitioners as an adjective to describe palpatory findings associated with altered tissue texture, and is frequently not defined. Generally, what is considered high stiffness in engineering is commonly related to ‘harder’ or altered tissue texture in clinical field.

Implications of abnormal tissue stiffness in the human body

In the human body, both higher or lower tissue stiffness changes, can be a parameter that in many cases, is associated with pathological conditions (Correas et al., 2013). Depending on the tissue involved and the pathology implied, stiffness may behave differently. An example is a cancerous tumour, which may manifest clinically as 'higher stiffness' of the tissues when compared to adjacent normal tissue (Itoh et al., 2006). However, not all pathologies are associated with higher stiffness, for example, tendons with tendinopathy have been reported to have weak and soft elastic structures (i.e. low stiffness) compared to healthy tendon (Arya & Kulig, 2010).

## 2. STIFFNESS IN THE MUSCULOSKELETAL FIELD

The three main tissues of interest of this section are muscle, tendon and fascial tissue. The following section will expand on these tissues in relation to the association of stiffness and the implications on the tissue affected. Firstly, muscle tissue will be reviewed followed by tendon and fascia.

Clinical implications for muscle stiffness

Muscle stiffness can often reflect the presence of dysfunction or pathology. People with neuromuscular disorders such as spasticity (Kesikburun et al., 2015), acute inflammatory disorders like myositis (Botar-jid et al., 2010), and in muscular dystrophies (Lacourpaille et al., 2015) have been found to have altered stiffness in the affected muscles. Increases in passive muscle stiffness has also been related to acute (Simons & Mense, 1998), and also chronic pain (Kuo, Jian, Wang, & Wang, 2013). Increased stiffness has been found in people experiencing delayed-onset muscle soreness (Niitsu, Michizaki, Endo, Takei, & Yanagisawa, 2011), and in people with myofascial trigger points (Sikdar, Shah, Gilliams, Gebreab, & Gerber, 2008).

In muscle tissue, higher stiffness is often a reflection of improved and clinically favourable quality of muscles. However, extreme stiffness can be a parameter of low quality in muscle,

therefore numerous treatment options aiming to improve this tissue quality have been developed including passive stretching (Akagi & Takahashi, 2013), massage (Crommert et al., 2015; Weerapong, Hume, & Kolt, 2005) and soft tissue mobilisation (Hopper et al., 2005). Very low muscular stiffness has also been associated with decreased explosive muscle strength, especially in the elderly population which could increase the risk of fall especially when lower limb muscles are affected (Akagi, Yamashita, & Ueyasu, 2015).

Muscle 'tightness' is commonly defined as a clinical musculoskeletal dysfunction which is associated with altered viscoelastic properties of the muscle (Liebenson, 2007). When a muscle is passively stretched it exhibits a resistance, this is often referred to clinically by practitioners as 'stiffness', or 'tightness' (Schleip et al., 2006). Tightness is often used interchangeably with stiffness referring to the presence of lack of flexibility and presence of rigidity. Tightness can occur as a consequence of many factors such as posture imbalances, overuse, injury, pain and pathological conditions (Baddar et al., 2002; Hertling & Kessler, 2006; Moseley & Adams, 1991; S. S. Wang, Whitney, Burdett, & Janosky, 1993). Increased muscle tightness has been shown to be a major risk factors for musculoskeletal injuries in sport (Witvrouw, Lieven, Peter, D'Have, & Cambier, 2003), and may predispose to developing compensatory movement patterns (You et al., 2009). Hence, identifying stiffness in muscle has important implications both in sports and in clinical setting, as assessment can lead to practitioners' implementing treatment and preventative strategies to prevent or mitigate dysfunction in an effort to minimise injury.

Daily motor activities can frequently be altered by abnormal changes in skeletal muscle stiffness (Chila & American Osteopathic Association, 2011), and tissue alteration and dysfunctional movement patterns have been linked to increased stiffness of muscle and other soft tissues (Sahrmann, 2002). Hypertrophic muscles have been correlated with increased stiffness of the muscle (Akagi, Chino, Dohi, & Takahashi, 2012), and increased muscle stiffness can potentially limit and restrict normal motion at the involved joint contributing to the development of compensatory movement patterns in adjacent areas. When stiffness limits range of motion in an area, in order to maintain normal function, the restriction must be compensated by contiguous more flexible joints in a uncontrolled manner (Sahrmann, 2002).

The more flexible joints are then predisposed to repetitive uncontrolled movement which can eventually result in tissue pathology (Comerford & Mottram, 2001).

#### Tendon stiffness functional and clinical implications

In tendon, the stiffness characteristics are essential parameters for effective performance and function. Adequate stiffness is required for force transmission and energy dissipation to occur during functional activities (D. L. Butler, Grood, Noyes, & Zernicke, 1978), but these properties can be altered in pathological conditions. Tendinopathies have been found to be associated with reduced stiffness, potentially predisposing the tendon to injury and prolonged recovery time (Arya & Kulig, 2010). Tendons that have been surgically repaired have been found to appear abnormally stiffer than normal and associated with a heterogeneous structure (Tan et al., 2012).

#### Clinical consequences of fascial stiffness

There has been considerable recent interest in studying the mechanical properties of fascia because it may relate myofascial pain and musculoskeletal dysfunctions (A Stecco, Gesi, Stecco, & Stern, 2013; C. Stecco et al., 2011). To date, a lot of this research has focused on histological and anatomical features of fascia. Fascia is a complex structure, composed generally by at least two membranous layers of collagen tissue (Benetazzo et al., 2011). Increased stiffness or ‘densification’<sup>1</sup> in fascial tissue compromises the sliding abilities of these layers within each other and with the surrounding structures (Langevin et al., 2011; Antonio Stecco, Meneghini, Stern, Stecco, & Imamura, 2013). This malfunction may result in dysfunction and is thought by some authors to be associated with conditions such as myofascial pain syndrome (Luomala et al., 2014; Pavan, Stecco, Stern, & Stecco, 2014; C. Stecco, Pavan, Pachera, De Caro, & Natali, 2014). Altered fascial mechanical structure has been identified in people diagnosed with low back pain (Langevin et al., 2011) and chronic neck pain (Antonio Stecco et al., 2013). Restoring the sliding abilities of the layers and reducing the stiffness of deep fascia have been proposed as potential treatments for myofascial pain syndrome (Luomala et al., 2014). Understanding the mechanical behaviour

---

<sup>1</sup> ‘Densification’ is a term often used to indicate fascial alterations which relate to an increase in the density of fascia (Pavan et al., 2014)

of fascia may contribute to improved understanding of musculoskeletal pathologies and it may also offer new insights and a deeper understanding of treatments directed at fascia.

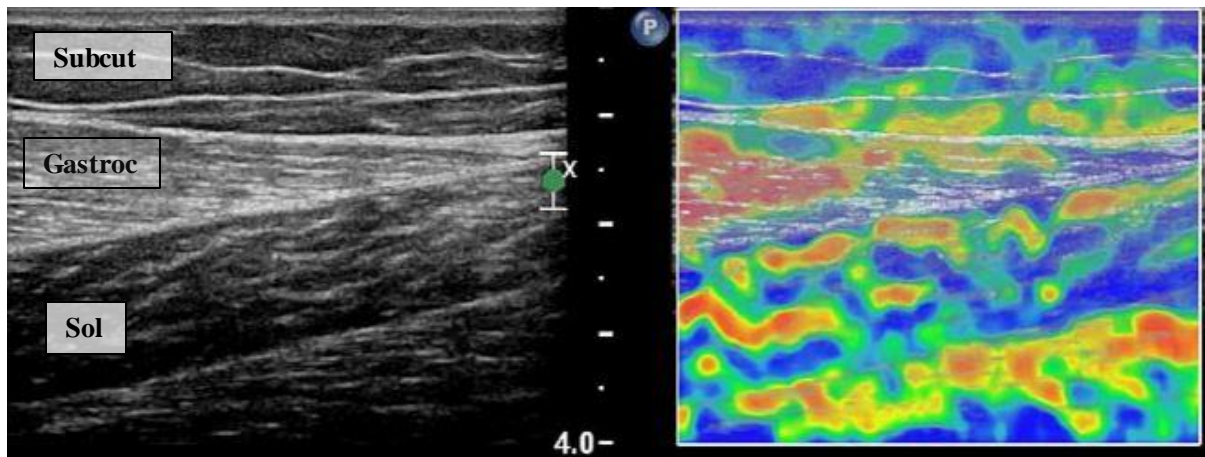
### 3. DIFFERENT ELASTOGRAPHY METHODS

This section will include a general description of elastography followed by a description of the different applications of elastography in magnetic resonance, and ultrasound imaging. The advantages and disadvantages of each of these methods will be discussed.

The term ‘elastography’ was first introduced to describe a technique in which the tissue strain resulting from external compression which was measured using ultrasound, providing a qualitative impression of the stiffness of tissue (Ophir, Céspedes, Ponnekanti, Yazdi, & Li, 1991). Elastography applications were developed to improve the diagnostic capability of traditional imaging techniques such as magnetic resonance imaging and ultrasound by delineating the differential stiffness of healthy and unhealthy tissues (Li & Snedeker, 2011). Elastography was developed to identify the viscoelastic properties of soft tissue, to recognise pathological conditions and provide objective evidence regarding the status of a disease in different tissues (Sarvazyan et al., 2011).

In general, all methods testing viscoelastic properties of tissue, involve measurements of deformation in response to applied stress or force, elastography relies on this same principle. All elastography imaging approaches, operate following three basic steps: (1) excitation (stress) or distortion to the tissues of interest, (2) observing tissue response (strain) and, (3) processing the distortion (Drakonaki, Allen, & Wilson, 2009). Tissue distortion can be applied in different ways including manual push, mechanical vibration, or a high frequency mechanical wave (Sarvazyan et al., 2011).

In all forms of elastography, results are visually displayed to the operator through a colour coded image called an elastogram and/or are also presented with numeric values (Ophir et al., 1999). The elastogram is typically displayed alongside a conventional image, by employing a combination of different colours to represent the different stiffness values of the assessed structure (see figure 1).



**Figure 1.** Ultrasound B-mode image with elastogram of subcutaneous tissue, the gastrocnemius and soleus muscles. The left hand panel shows the B-mode image of the lateral gastrocnemius and soleus muscles, ultrasound scan with the corresponding to the ARFI elastogram image on the right. Abbreviation: *subcut*= subcutaneous tissue, *gastroc*= lateral gastrocnemius muscle and *sol*= soleus muscle. Copyright © 2016 [COPYRIGHT PAULA TOLEDO].

### Magnetic resonance elastography

Magnetic resonance elastography is an imaging technique that can assess the stiffness of soft tissues by measuring the shear modulus of these tissues by using of mechanical waves (Muthupillai et al., 1995). The technology is becoming increasingly available as an additional feature of conventional MRI scanners (Manduca et al., 2001). Magnetic resonance elastography allows a non-invasive, *in vivo* assessment of the mechanical properties of tissue (Oida, Amano, & Matsuda, 2004). The mechanical waves can travel through to deep soft tissues on the patient's body. By measuring the local wavelength of the strain waves, the elasticity of tissue is obtained (Oida et al., 2004). Magnetic resonance elastography has been identified as a reliable and safe method for the diagnosis of pathological stiffness in the liver (Mariappan, Glaser, & Ehman, 2010) and breast (Xydeas et al., 2005). The most common clinically documented application has been for the assessment of liver pathologies, such as hepatic fibrosis, which has shown to be associated with increased stiffness of liver tissue (Mariappan et al., 2010; Yin et al., 2007). Ongoing investigations are being undertaken to identify the potential clinical applications of magnetic resonance elastography on other soft tissues. Normative research of healthy and pathological organs are being undertaken to describe the changes of stiffness in various conditions, some of these studies include the brain (Kruse et al., 2008), thyroid (Bahn et al., 2009), heart (Kolipaka, Araoz, McGee, Manduca, &

Ehman, 2010), breast (Sinkus et al., 2005), fascia (Q. Chen, Bensamoun, Basford, Thompson, & An, 2007) and skeletal muscles (Bensamoun et al., 2006; Drakonaki & Allen, 2010; Ringleb et al., 2007).

*Advantages and disadvantages of magnetic resonance elastography.*

There are three major advantages for the use of magnetic resonance elastography. Firstly, it provides a three-dimensional quantitative map of soft tissues stiffness of the whole body. Secondly, it can assess tissues, such as the brain, that are not accessible through other methods (Mariappan et al., 2010). Thirdly, it also has the advantage of being less operator dependent, and has a lower rate of technical failure compared to ultrasound elastography (Venkatesh, Yin, & Ehman, 2013). On the other hand, magnetic resonance elastography can be time-consuming, more expensive and less accessible than UES. Hence its incorporation into rehabilitative clinical practice is unlikely.

Ultrasound elastography

Ultrasound elastography (UES) is the first and most widely studied elastography modality (Li & Snedeker, 2011). Given the growing general interest, the number of available techniques, and level of scientific evidence in this field, in 2011 the European Federation for Ultrasound in Medicine and Biology (EFSUMB) recognised the need to develop guidelines and recommendations for the clinical use of ultrasound elastography (Bamber et al., 2013).

The use of UES protocols in clinical practice are well established for the diagnosis of various disease conditions of varying human tissues and organs. The use of UES in liver has by far the largest body of evidence (Barr, 2012). It was initially evaluated in patients with chronic hepatitis C and later in other chronic hepatopathies (Cosgrove et al., 2013). The large quantity of evidence has allowed for UES to be widely used in the clinical setting for diagnosing a wide range of liver diseases characterised by affecting liver stiffness. There are now numerous meta-analyses available in the literature that have investigated the usefulness of UES for detecting various liver diseases (Bota et al., 2013; Talwalkar, Kurtz, Schoenleber, West, & Montori, 2007; Tsochatzis et al., 2011), and for discriminating benign from malignant masses on the pancreas (Mei, Ni, Liu, Jin, & Sun, 2013), breast (Gong et al., 2011), thyroid (Bojunga et al., 2010), prostate (Aboumarzouk et al., 2012) and lymph nodes

(W. Xu et al., 2011). While the primary clinical application of UES remains for tumour detection, its potential application to musculoskeletal tissues has increasingly driven research activity. However, these investigations are still small scale studies, and stronger evidence is needed in this field (Bamber et al., 2013). The application of UES in musculoskeletal structures will be further reviewed later in this section (see numbering 6 of Part A).

#### *Advantages and disadvantages of ultrasound elastography*

Ultrasound elastography has many advantages compared to magnetic resonance elastography in clinical application. The most important aspect is its convenience as UES allows for real-time visualization, is relatively simple to use, non-invasive, portable and associated with lower operating cost compared to magnetic resonance elastography (Drakonaki & Allen, 2010; Gennisson, Cornu, Catheline, Fink, & Portero, 2005). The main challenge facing UES is the issue of measurement reproducibility. Many investigations have mentioned concern regarding the inherent operator-dependency of this technique and argue that special training is required to improve performance (Goddi, Bonardi, & Alessi, 2012; Jeong et al., 2014). However, some authors have found this technique to be a highly reproducible and user-friendly technique (Fraquelli et al., 2007). These reliability aspects are further discussed in Part B of this review.

#### 4. ULTRASOUND ELASTOGRAPHY TECHNIQUES

Various ultrasound elastography techniques are available, and each rely on different methods to produce and measure tissue deformation. These are classified according to the way tissues are stressed or displaced and the algorithm used to construct the image (Garra, 2011).

The various ultrasound elastography techniques often receive different names in the literature, which can cause confusion amongst readers, hence a classification system of the different techniques is now available (Bamber et al., 2013). All UES techniques can be grouped into two main categories: (1) quasi-static and (2) dynamic. Quasi-static methods, refer to techniques where an external force is applied to the tissue, like strain elastography. While dynamic methods include shear-wave, acoustic radiation force and transient elastography, where the source of stress comes from the same ultrasound probe. In clinical practice the most used techniques include strain UES, shear-wave UES, transient and acoustic radiation UES (Drakonaki et al., 2009; Drakonaki & Allen, 2010).

#### 4.1 Strain elastography

Strain elastography is also known as compression UES, sonoelastography, real-time elastography and quasi-static elastography. This technique involves the application of manual compression with a hand-held ultrasound transducer applied to the tissues of interest (Brandenburg et al., 2014). Tissue deformation, represented by strain, is measured in a two-dimensional (2D) region under the transducer and is displayed as an elastogram. Given the same amount of applied stress, softer tissue have more deformation and therefore undergo larger strain than stiffer tissue. Hence, the amount of tissue deformation is inversely proportional to the tissue stiffness (Drakonaki et al., 2009). Strain UES has mainly been used in the field of oncology, in identifying masses in the breast (Zhu et al., 2008), prostate (Zhang et al., 2014), lymph nodes (Ying et al., 2012) and thyroid (EL-Hariri, Taha Ali, Tawab, Magid, & EL-Shiekh, 2014). In recent years its popularity in musculoskeletal field has increased noticeably. Most research in this field has focused on describing the mechanical properties of healthy and pathological Achilles tendon (Brown, Alsousou, Cooper, Thompson, & Noble, 2013; De Zordo, Fink, et al., 2009; Sconfienza, Silvestri, & Cimmino, 2010; Tan et al., 2012). Although there is growing interest in investigating the normal and pathological characterization of skeletal muscle and tendon with strain elastography, reliability is an issue that needs clarification.

Strain elastography has some limitations, because the compression is manually applied and therefore includes operator dependent factors such as the level of transducer pressure, depth reached and probe alignment (Drakonaki, Allen, & Wilson, 2012). The information derived from strain UES is predominantly qualitative (Drakonaki et al., 2012). Despite of these limitations, this is the most commonly used UES technique in clinical settings and in research (Drakonaki et al., 2009, 2012), possibly due to the availability of this method in commercially available ultrasound scanners.

#### 4.2 Shear-wave ultrasound elastography

Shear-wave UES uses a combination of two different sonographic waves: a shear-wave which can provide stiffness information and an ultrasonic-wave that gives the spatial resolution (Correas et al., 2013; Drakonaki et al., 2009). In this technique the speed of the shear-wave through the tissues is measured, hence the stiffer the medium, the faster the

waves will move. By solving the shear-wave equations, quantitative estimates of soft tissues stiffness values can be derived, and stiffness is expressed in kPa or in  $\text{m.s}^{-1}$  (Brandenburg et al., 2014).

Shear-wave UES has been described as a promising technique because it is less operator dependant than strain elastography as it does not require external manual compression applied by the operator and has the advantage of providing more objective outcomes (Correas et al., 2013). A potential drawback with this technique is that the assessment of superficial tissues is limited, as a certain depth is required for the shear-wave to penetrate.

Shear-wave UES has shown clinical utility in breast (Chang et al., 2013), thyroid (Azizi et al., 2015), kidney (Bob et al., 2014), liver (Ferraioli, Parekh, Levitov, & Filice, 2014) and prostate (Barr, Memo, & Schaub, 2012). The technique has only recently been assessed on musculoskeletal tissue and so far there is limited experience of this method (Correas et al., 2013). Exploratory data is available using shear-wave elastography describing the elastic properties of normal and pathologic tendon (Arda, Ciledag, Aktas, Aribas, & Köse, 2011; Brum, Bernal, Gennisson, & Tanter, 2014; X.-M. Chen et al., 2013) and muscle (Arda et al., 2011; Eby et al., 2015b). The feasibility and repeatability of this method for the evaluation of muscle has also been explored and found to be acceptable (Dorado Cortez et al., 2015; N. Miyamoto, Hirata, Kanehisa, & Yoshitake, 2015; Rosskopt, Ehrmann, Buck, Gerber, & Flück, 2016; Yoshitake, Takai, Kanehisa, & Shinohara, 2014). Further consideration of the reliability of this method will be examined in Part B of this review.

#### 4.3 Transient ultrasound elastography

Transient UES also known as vibration-controlled elastography is considered a subcategory of shear-wave elastography (Afdhal, 2012). The velocity of the shear-waves emitted by the transducer are measured as they pass through the tissue of interest. The shear-wave speed can then be converted into a quantitative stiffness value, expressed in kilopascals (Afdhal, 2012). This technique has been mainly used for the diagnosis of liver dysfunction (Sandrin et al., 2003). There are some studies using transient UES for the examination of tendon and muscle stiffness, such as Gennisson et al. (2003, 2005) who aimed to quantify stiffness changes with different levels of muscle contraction, and Nordez et al. (2008) who

investigated the effect of passive stretching on skeletal muscle stiffness. However, transient UES technique has gained most of its popularity for the diagnosis of liver diseases.

#### 4.4 Acoustic radiation force impulse

Acoustic radiation force impulse (ARFI) employs short duration acoustic radiation forces to generate distortion in the tissues, causing tissue displacement which can then be detected and mapped (Nightingale, Soo, Nightingale, & Trahey, 2002). ARFI does not need external compression so the operator dependency is reduced compared to strain elastography (Li & Snedeker, 2011). The tissue displacement is inversely proportional to the stiffness of the tissues, thus stiffer tissues exhibits less displacement than more compliant ones. This method has improved imaging accessibility to deep tissues and is associated with less distortion when compared to shear-wave (Nightingale et al., 2002). A major advantage of ARFI is that neighbouring tissue does not produce confounding artifacts – as occurs for shear-wave and strain UES. Sporea et al, (2013) found ARFI to be more accurate in the diagnosis of hepatopathies when compared to shear-wave and transient elastography. ARFI is more often clinically used for the assessment of the kidney (Bob et al., 2014; Nightingale, Soo, et al., 2002; Syversveen et al., 2012) and the liver (Friedrich-Rust et al., 2009; Sporea et al., 2013). Two recent meta-analysis showed that ARFI is highly sensitive for detecting nodules on the thyroid (B.-J. Liu et al., 2015), and for differentiating between benign and malignant breast masses (B. Liu et al., 2015).

To date, it appears that there are only five studies that have used ARFI for the evaluation of muscle stiffness: (1) Nightingale et al. (2002) aimed to examine whether ARFI could detect stiffness changes *in vivo* in the vastus lateralis at different loading conditions. They concluded that ARFI is capable of quantifying tissue mechanical properties. Further investigations are needed as this study only used a small sample size (n=3). (2) Kuo et al. (2013) conducted a pilot study to standardize the stiffness assessment of neck muscle stiffness in healthy individuals and to document a normal range of stiffness values for these neck muscles. This study found ARFI to be a feasible method for this purpose. (3) Badea et al. (2014) aimed to quantify the stiffness values of the masseter muscle in healthy people and in patients who had undergone head and neck radiation therapy. It was concluded that ARFI is a feasible method to evaluate the stiffness of this muscle in both health and in those who

had undergone neck radiation therapy. (4) Yavuz et al. (2015) evaluated the feasibility of ARFI to assess the stiffness of the bicep brachii muscle at different levels of isometric contraction in healthy people. The method was reported to be a feasible and simple method that can be used to determine changes in muscle stiffness with isometric contractions. (5) Cho & Nam (2015) used ARFI to characterize the viscoelastic properties of lower limb muscles in people with spinal cord injury.

All these studies provide valuable information about the potential use of this technique, however, these studies are preliminary studies which were conducted using small sample sizes, hence studies with larger samples are needed. Furthermore, improving the understanding of the *intra*- and *inter*-operator reliability of ARFI in muscle would be the next step forward to further determining the prospective clinical use of ARFI for diagnosing and screening of healthy and pathological muscle states.

## 5. METHODS OF ELASTOGRAM INTERPRETATION AND ANALYSIS

All elastography imaging report relative findings on an elastogram, which is a colour coded map representing the variable stiffness of the region of interest. The elastogram is generated by software and usually represented in a semi-transparent overlay of the grey scale ultrasonographic image (Carlsen, Ewertsen, Lönn, & Nielsen, 2013). The grey or coloured scale encoding is selected by the user. Most often red is chosen for encoding 'softer' tissue, blue for 'hard' and yellow/green for 'intermediate stiffness' (see figure 1).

Because of inherent problems related to the quantitative assessment of UES imaging, several scoring systems have been developed to improve the interpretation of elastographic outcomes. An elastography score can help clinicians make better management decisions. Carlsen, Ewertsen, Săftoiu, Lönn, & Nielsen (2014) categorize the different scoring systems into qualitative, semi-quantitative and quantitative, as these will be reviewed in the following section.

## 5.1 Qualitative method

### *Visual grading system*

Various medical specialties have developed their own particular visual methods to interpret elastograms depending on the body part being studied. The main feature investigated uses ‘eye ball’ or visual analysis of the colour distribution and heterogeneity of the colour tone in the region of interest, however, some authors also include the size of the lesion and presence of abnormal tissue texture (Drakonaki et al., 2009; Itoh et al., 2006; G. Xu et al., 2014). For instance, Itoh et al. (2006) proposed a five colour scoring-scale for assessing the malignancy of breast cancer with strain elastography. A scoring system for Achilles tendon has also recently been validated, which categorizes images according to the colour dominance and its distribution in the elastogram (Klauser, Faschingbauer, & Jaschke, 2010). The reliability of visual inspection for the Achilles tendon by two radiologists for determining the elastographic characteristic was found to have “acceptable reliability” (Drakonaki et al., 2009), however, an earlier study found this scoring system to be unreliable (Park et al., 2009).

## 5.2 Semi-quantitative methods

### 5.2.1 *Histogram of pixel distribution*

Săftoiu et al. (2008) proposed a semi-quantification system called hue histogram analysis for the interpretation of elastography imaging. The hue histogram is a graphical representation of the colour distribution (hues) in a selected image field. Each pixel of an image is represented with a numerical value which ranges from 0 to 256, where, by convention zero usually represents the ‘hardest’ tissue and 256 the ‘softest’. Hue histograms are obtained based on UES data for a manually selected region of interest within the standard elastogram. The descriptive statistics (mean, standard deviation) of the different pixel numeric values are calculated from the pixel distribution on the elastogram and expressed in arbitrary units, which is then used as an indirect representation of tissues mean stiffness (Orlacchio et al., 2012). A limitation of this method is that the elastogram must be analysed *after* acquisition of the imaging with different image processing software applications such as ‘ImageJ’ (Schneider, Rasband, & Eliceiri, 2012), ‘Elasto’ (proprietary software owned by Hitachi), or ‘MyLab’ (Gheonea et al., 2010; Paparo et al., 2014). The selection of the image to be analysed is operator dependant, which could hamper the processing of the outcomes (Gonçalves, Soares, & Bastos, 2015). This method of calculating the mean tissue stiffness is

one of the simplest methods employed to obtain semi-quantitative information from elastogram and has been widely used, especially in the analysis of malignancy in breasts (Moon et al., 2010), pancreas (Opačić, 2015; Săftoiu et al., 2011), myositis (Botar-Jid et al., 2010), and liver (Gheonea et al., 2010; Saftoui, Gheonea, & Ciurea, 2007). Săftoiu et al. (2011) used hue histograms for analysing UES images of pancreatic masses and reported good sensitivities ( $S_n = 93.4\%$  and  $91.4\%$ ) but varying specificities ( $S_p = 66.0\%$  and  $87.9\%$ ). Carlsen et al. (2014) evaluated the ability of visual scoring, strain-ratio and hue histogram to predict the stiffness of a tissue mimicking phantom and found that strain-ratios and hue histograms are superior to visual scoring. Given that hue histogram shows promise as a method of quantifying elastograms, and there only exists a few studies of musculoskeletal tissues using hue histograms, there appears to be potential for future studies to assess stiffness using this method.

### 5.2.2 *Strain-ratio*

Strain-ratio measurements have been introduced as a method of interpreting an elastogram in a more objective way, through providing information on relative tissue strain. Ratio measurement are obtained by comparing two areas of strained material without knowledge of the exact compression force applied and by the assuming that the same amount of stress is applied to both materials (Havre, Waage, Gilja, Odegaard, & Nesje, 2011). Strain-ratio has been reported to be a more accurate diagnostic tool than conventional visual scoring systems for thyroid nodules (H. Wang et al., 2013), and for breast cancer (Zhi et al., 2010).

### 5.3 Quantitative method

Quantitative elastographic techniques like shear-wave have the advantage that by measuring the speed of the wave travelling through the tissues it can provide an objective measurement of tissue elasticity (Klauser, Faschingbauer, & Jaschke, 2010). On the elastogram each colour is represented by a numeric value, a direct measure of tissue stiffness is thereby achieved. These values are generally obtained by calculating Young's modulus and expressed in units such as kilopascals (kPa) or velocity ( $m.s^{-1}$ ), conveying quantitative information about local viscoelastic properties of tissues. The level of stiffness determines the speed of propagation of the wave through the tissues, for example, shear-waves will move

faster through stiffer tissues as the speed of the waves propagating through the tissues is directly proportional to the stiffness (Klauser et al., 2010).

#### Elastography summary

In conclusion, magnetic resonance elastography and UES each have important advantages and disadvantages. The main strength of both methods is they are non-invasive and can provide real-time measurements of stiffness. The key advantages of magnetic resonance elastography is that it offers three dimensional imaging and can access deeper structures than UES. However, magnetic resonance elastography is more expensive, time consuming and less accessible than UES. While UES is more operator dependent, there is evidence to show that this method is of acceptable reliability. Furthermore, UES has the potential to develop as a pre and post-treatment measurement tool in clinical settings.

There are four main UES techniques that have been widely used for the examination of different human tissues. Three of these techniques (shear-wave, transient and ARFI) provide more objective measures of stiffness and are less operator dependant as tissue stress is applied internally by the probe, whereas strain elastography requires an external application. Although there are three main methods to interpret an elastogram. Qualitative methods appear to be of debatable reliability and are highly operator dependant. However, this method is widely used in several medical fields. Semi-quantitative methods have improved reliability and less operator dependence than visual scoring, however, these methods provide an indirect stiffness value. Quantitative methods seem to provide the most objective and direct measure of stiffness.

## 6. APPLICATION OF ULTRASOUND ELASTOGRAPHY IN MUSCULOSKELETAL STRUCTURES

### Introduction

In recent years there has been growing interest in using this UES for musculoskeletal tissues as it provides information about the mechanical properties of myofascial tissue. Ultrasound elastography is being investigated, and its clinical applicability for diagnostic and monitoring

in the musculoskeletal field appears to hold potential, as will be discussed in the following section.

There are a range of different applications of UES in the musculoskeletal field including at the level of diagnosis of pathology based on identifying associated tissue stiffness changes, and as a test-retest tool following treatment and in research.

### 6.1 Usefulness of UES in characterising normal and abnormal soft tissue stiffness.

Characterising normal soft tissue data using UES is essential for describing the normal state of tissue and for establishing standardised knowledge about illnesses and clinical conditions. Efforts to describe normative data of the mechanical properties of normal and damaged musculotendinous structures using UES have been undertaken. The main body of research has focused in describing tendon stiffness in both healthy (Arda et al., 2011; X.-M. Chen et al., 2013; De Zordo, Fink, et al., 2009; Drakonaki et al., 2009; Kubo, Kanehisa, & Fukunaga, 2003), and in pathological processes (X.-M. Chen et al., 2013; De Zordo et al., 2010; Sconfienza et al., 2010; Tan et al., 2012). In addition to tendon, muscle has also been investigated in healthy people (Arda et al., 2011; Badea et al., 2014; Chino, Akagi, Dohi, & Takahashi, 2013; Eby et al., 2015b; Lacourpaille, Hug, Bouillard, Hogrel, & Nordez, 2012), and in abnormal conditions such as myositis (Botar-Jid et al., 2010), spasticity (Kesikburun et al., 2015), myofascial pain syndrome (Kuo et al., 2013), and in Duchenne muscular dystrophy (Lacourpaille et al., 2015). However, drawing conclusions to establish normative data about the stiffness characteristics of these tissues is particularly difficult as different stiffness descriptors and methodological designs have been employed.

### 6.2 Stiffness in muscle activation during fatigue and/or pain

Ultrasound elastography has also been used to investigate muscle activation strategies during fatigue and/or pain. The effects of selective muscle fatigue (i.e., one muscle of the quadriceps) on load sharing strategies during simple tasks was assessed using UES (Bouillard et al., 2014). The shear-modulus of the muscles was considered an index of muscle force, providing information about muscular adaption and compensate strategies to fatiguing tasks. Ultrasound elastography may be therefore used to provide further insights into the aetiology of some musculoskeletal conditions, such as patellofemoral syndrome which has been

suggested to be due to unbalanced load sharing among synergists (Coqueiro et al., 2005). Ultrasound elastography has also been used to investigate the redistribution of motor unit activity within a muscle during experimentally induced acute pain while performing a simple task (Tucker, Hodges, Van Den Hoorn, Nordez, & Hug, 2014). Understanding the adaptations that occur within a muscle during the presence of pain, may help understand compensations strategies as protection mechanisms to avoid further pain or injury. This research has opened opportunities to produce similar research with more complex tasks, where there is greater opportunity for compensation.

### 6.3 Muscle stiffness through life-span and by sex

Skeletal muscle stiffness has been shown to change through life-span and by sex. Recently, Ryota Akagi et al. (2015) investigated these differences in lower limb muscles and found a reduction of stiffness in the elderly ( $\geq 65$  years of age). Eby et al. (2015a) when investigating the muscle stiffness differences by sex, concluded that the shear modulus values tended to be higher for females than for males of the same age (mean age 44 years [range 21-94]). These studies are the first to report results towards the establishment of normative data for skeletal muscle shear modulus throughout adulthood and sex, however, well designed studies to inform knowledge of measurement reliability are necessary to interpret these data.

### 6.4 Ultrasound elastography for diagnosing varied musculoskeletal dysfunctions and pathologies

Ultrasound elastography is emerging as a promising method for evaluation and early diagnosis of dysfunctional or pathological musculotendinous tissue states. Pathological changes have been documented using UES. For example, Sikdar et al. (2008) found UES to be feasible for differentiating myofascial trigger points<sup>2</sup> from the adjacent healthy tissues in the upper trapezius. Where there were palpable trigger points, UES showed increased stiffness. Ultrasound elastography may therefore be a step towards characterising and objectively identifying these abnormalities, which helps with establishing a diagnostic

---

<sup>2</sup> Myofascial trigger points: are palpable hyperirritable stiff nodules within a taut band of a skeletal muscle that are sometimes associated with chronic musculoskeletal pain (Sikdar et al., 2008).

criteria, which would be expected to be more reliable, sensitive and specific than palpation which has been strongly criticised, on the basis of poor rater reliability (N. Lucas, Macaskill, Irwig, Moran, & Bogduk, 2009).

Improving the knowledge about the reliability of UES could also help identify other stiffness changes following dysfunction and pathology. For example Langevin et al, (2011) investigated the stiffness qualities of the thoracolumbar fascia in patients with chronic low back pain with UES and reported lower shear-strain was present in people with chronic low back pain compared to healthy people. These differences in stiffness could provide possible clues as to the aetiology of low back pain, but longitudinal rather than cross-sectional study designs are necessary. Similarly, lower and heterogeneous distributions of stiffness were identified in ruptured Achilles tendon compared with the normal tendons (X.-M. Chen et al., 2013). Distinctly reduced stiffness was identified in patients with tendinopathies for both the Achilles tendon (De Zordo et al., 2010), and for the lateral epicondylitis (Ahn, Kang, Hong, & Jeong, 2014). De Zordo, Lill, et al. (2009) assessed the feasibility of UES in the diagnosis of lateral epicondylitis by comparing the findings to those obtained at clinical examination, and during ultrasonography. They concluded that UES can be used to differentiate healthy from symptomatic lateral epicondyle with excellent correlation with ultrasound and clinical examination findings. Ultrasound elastography could have promising application as a supplementary method to traditional imaging techniques for the diagnosis of tendon abnormalities in the common extensor tendon and the Achilles tendon by providing additional functional information.

Ultrasound elastography may also contribute to the clinical assessment of muscular pathologies. Increased stiffness has been associated with Duchenne muscular dystrophy (Lacourpaille et al., 2015). Elastography has been reported to facilitate the diagnosis of inflammatory myopathies by assessing the viscoelasticity properties of the affected muscles (Botar-Jid et al., 2010).

## 6.5 Ultrasound elastography for the assessment of treatment and rehabilitation outcomes

The effect of specific treatment techniques which are commonly used in the treatment of several pain conditions have been assessed using UES. Luomala, Pihlman, Heiskanen, &

Stecco, (2014) investigated the effect of performing a fascial release to improve the stiffness of the lower leg deep fascia in patient with calf pain, showing noticeable improvements both in pain and in fascial stiffness. Turo et al, (2015) found positive changes in myofascial trigger point texture following application of three dry needling treatments using UES as an assessment tool. A short-term study using UES was able to detect the effect of steroid injections on tendon stiffness in people with ‘trigger finger’ (H. Miyamoto et al., 2011). Similarly, a short term effect on muscle stiffness was reported after the application of massage on muscle when examined with UES (Crommert et al., 2015). These recent studies demonstrate usefulness of UES in investigating the treatment mechanisms on soft tissue stiffness.

### *Rehabilitative ultrasound imaging*

The use of ultrasound has been expanded outside the traditional radiology field and is now used by practitioners in musculoskeletal, rehabilitation and in sports medicine, especially by physiotherapists (McKiernan, Chiarelli, & Warren-Forward, 2013; Potter, Cairns, & Stokes, 2012). Rehabilitative ultrasound imaging (‘RUSI’) is used mainly in physiotherapy clinics to evaluate muscle and related soft tissue morphology and function during exercise and physical tasks (D. Teyhen & Koppenhaver, 2011). This methodology has the potential to be used in conjunction with elastography software to assess the stiffness of muscle and other soft tissues. However, not all practitioners using rehabilitative ultrasound are formally trained in the use ultrasound imaging (Potter et al., 2012), hence there are a number of novice operators performing imaging for rehabilitation purposes. The reliability of *novice* operators (practitioners typical of practitioners using RUSI) should be determined as ultrasound can be used clinically in conjunction with elastography.

Some manual therapy techniques that are commonly used as part of rehabilitation programmes have been examined using UES to assess the stiffness changes on skeletal muscle. Akagi & Takahashi (2013) have been using this method to evaluate the changes observed on muscle when applying stretching techniques and reported an immediate reduction on muscles stiffness after static stretching. Ultrasound elastography was also used to monitor the increases of stiffness on muscle when performing eccentric exercise as a strengthening rehabilitation programme (Lacourpaille et al., 2014). Ultrasound elastography

may be a useful tool to objectively monitor pre and post stiffness qualities in muscles over the course of rehabilitation programmes and for the maintenance of adequate muscle condition post-rehabilitation.

The efficacy of rehabilitation strategies largely depends on the ability of patients to perform the rehabilitation tasks adequately, and UES can be used as a biofeedback tool to guide muscular retraining and in rehabilitation. Measurement of muscle stiffness with ultrasound elastography during contraction can provide patients and practitioners with estimated changes in muscle force (Bouillard, Nordez, & Hug, 2011; Hug, Tucker, Gennisson, Tanter, & Nordez, 2015). Ultrasound elastography has been shown to provide a more accurate estimation of individual muscle force than electromyography (Bouillard et al., 2011). Hence UES could be used as a substitute for electromyography to better understand the biomechanics of muscle function during rehabilitation exercises. Ultrasound elastography has also been used to assess the shear modulus of abdominal muscles during trunk stability exercises in people with low back pain (Mac Donald, Wan, Mc Phee, Tucker, & Hug, 2015), showing that UES could be of potential value in rehabilitation.

The supplementation of conventional ultrasound with elastography may allow clinicians to better tailor management of the affected musculoskeletal structure and determine a more accurate rehabilitation strategies to improve prognosis for patients (Ooi, Malliaras, Schneider, & Connell, 2014). However, the published literature about the UES remains limited across a range of applications and in number of investigations, hence further research is needed to better understand the potential clinical role of UES in the musculoskeletal field.

All these applications are valuable and promising for clinical application and undoubtedly more applications will emerge as more experience and scientific evidence is gathered. Given the wide range of uses of UES for the assessment of musculoskeletal structures, the need to better understand the *intra*-rater and *inter*-rater reliability between novice and experienced operators is essential.

## 7. THE LOWER LEG

The main aim of this thesis study involves the lower leg, hence a section on basic anatomy as background will be overviewed in this section. The lower leg region is an area of interest to many manual therapist and for rehabilitation as it is frequently subject to injury and pathologies. A brief overview of the anatomy of this area will be presented.

### 7.1 Anatomy of the posterior aspect of the lower leg

The leg is composed of anterior, lateral, superficial posterior, and deep posterior compartments (Frink, Hildebrand, Krettek, Brand, & Hankemeier, 2010). The posterior compartments together form the largest of the leg compartments and are separated from each other by a band of fascia called the crural fascia (C. Stecco et al., 2009). The superficial and deep posterior compartment are comprised of seven muscles. (O'Brien A., Edwards E., Finlayson J., & Kerr, 2012). The gastrocnemius and soleus are in the superficial compartment and all insert in the calcaneus via the Achilles tendon, these muscles together are known as triceps surae (Joseph, Lillie, Bergeron, & Denegar, 2012; O'Brien, 2005) (see Figure 2).

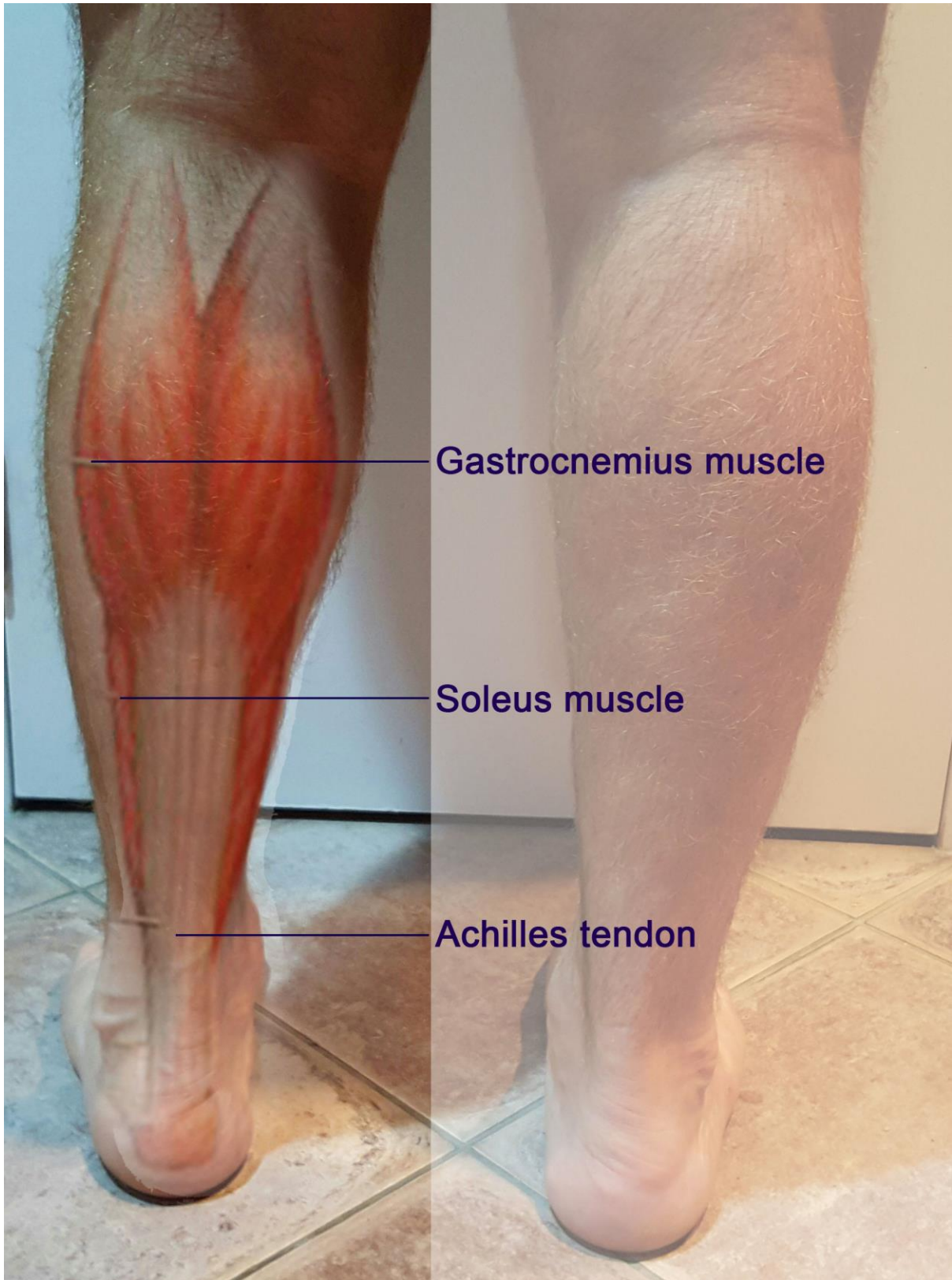

Figure 2. Image of the calcaneus and soleus muscle with the Achilles tendon. Copyright © 2016 [COPYRIGHT PAULA TOLEDO].

The gastrocnemius is the most superficial muscle of the compartment and originates above the knee and is characterised by the presence of fast twitch muscle fibres which allows it to produce forceful movements (Cohen, 2009; O'Brien, 2005). Its main function involves plantarflexion at the ankle, forward propulsion of the body during gait and running, and knee flexion. The soleus muscle originates below the knee, and therefore, has no direct action on the knee joint. The soleus is composed mainly of slow twitch fibres and it carries out plantarflexion at the ankle. The calf muscles (gastrocnemius and soleus) are considered to play a key role as a 'postural muscle', and are important in maintaining upright posture and work to stabilize the body (Solberg, Gur, & Adar, 2007). These muscles together, also act as a peripheral vascular pump (O'Brien, 2005), and contribute to maintaining circulatory health, particularly in venous return from the legs to the heart (O'Brien A. et al., 2012).

## 7.2 Injury, pathology and dysfunction of the lower leg

Lower leg injuries are common among athletes and non-athletes (Campbell, 2009; Counsel & Bredahl, 2010). In a systematic review van Gent et al. (2007) report that the second most predominant site of injury in long distance runners was the lower leg. Although studies documenting the injury rates of calf muscle tears are scarce, a prospective 8 year study involving 2,300 soccer players found that 13% of the muscle injuries sustained were injuries to the calf muscles, and the gastrocnemius is one of the most frequently injured muscles (Jan Ekstrand et al., 2011). Muscle strain presents one of the most frequently used terms to describe sports muscle injury, however, this term lacks clear definition and is used with high variability (Mueller-Wohlfahrt et al., 2013). Strain is a biomechanical term which is not well defined but used clinically to refer to different muscle injuries. Calf strains are commonly seen injuries in primary care and sports medicine clinics (Bryan Dixon, 2009), and typically occur during sudden ballistic movements involving the lower extremity, such as sprinting or jumping (Gallo, Plakke, & Silvis, 2012). The calf is considered to be a site of high risk of injury because of its action across two joints ('biarthrodial function'), its superficial location and because of the high density of fast twitch muscle fibres (Bencardino et al., 2000; Bryan Dixon, 2009). The combination of biarthrodial function and presence of fast twitch fibres can lead to excessive stretch and the rapid forceful contraction which may predispose to risk of injury.

Altered mechanical properties in the calf muscles such as lack of flexibility or increased tissue stiffness are thought to cause several biomechanical dysfunctions such as loss of range of motion at the ankle (dorsiflexion) or at the knee (extension) which can predispose to injuries and pathological conditions (Cohen, 2009; DiGiovanni, Kuo, Tejwani, Price, Hansen Jr., et al., 2002; McKay et al., 2001). Loss of ankle dorsiflexion is considered a key predisposing factor for many lower limb injuries (Terada, Pietrosimone, & Gribble) such as lateral ankle sprain (Neely, 1998; Tabrizi, McIntyre, Quesnel, & Howard, 2000), muscle strain (Witvrouw et al., 2003), plantar fasciopathies (Neely, 1998), tendinopathies (Backman & Danielson, 2011), stress fractures (Hughes, 1985; Kaufman, Brodine, Shaffer, Johnson, & Cullison, 1999), altered foot biomechanics that can lead to metatarsalgia (Cohen, 2009) and tibial stress syndrome (Kaufman et al., 1999).

The gastrocnemius and soleus muscles can also be affected by pathological conditions such as spasticity (Baddar et al., 2002), cramps (J. V Butler, Mulkerrin, & O'Keefe, 2002), myofascial trigger points (Prateepavanich, Kupniratsaikul, & Charoensak, 1999) and hypertrophy as a result of conditions such as Duchenne muscular dystrophy and Becker dystrophy (Emery, 2002). These conditions may have a negative effect on their viscoelastic properties and so will affect normal function (Given, Dewald, & Rymer, 1995).

Given the important role of tissue stiffness in this wide range of lower limb conditions and dysfunctions, the potential application of UES to objectively quantify stiffness is important and therefore reliability of UES to measure stiffness is necessary. Hence research investigating the *intra*-operator and *inter*-operator reliability of UES for the assessment of stiffness in muscles of the leg is required

## **PART B**

### RELIABILITY OF UES ON LEG STRUCTURES

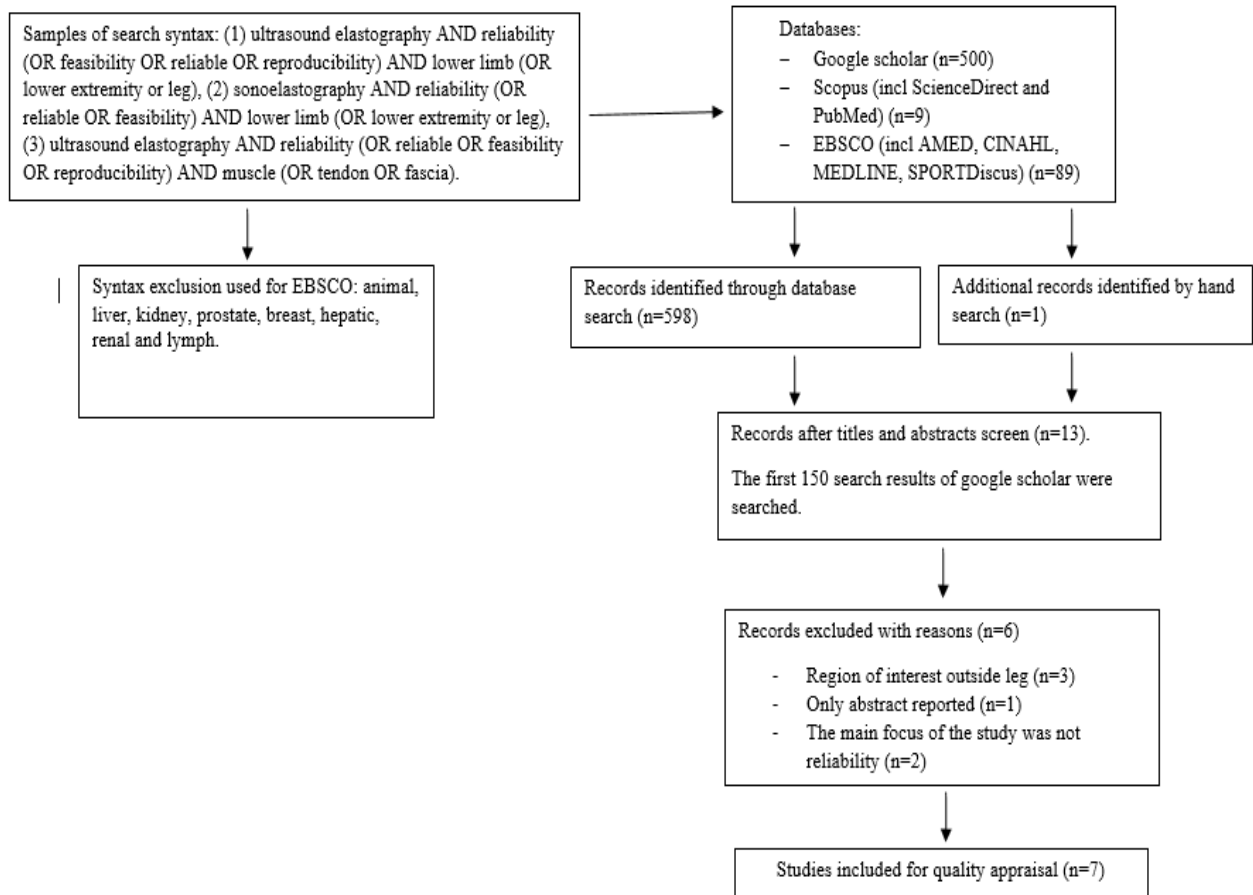
The aim of this Part B is to critically appraise studies that have investigated the reliability of ultrasound elastography when assessing muscles and tendons of the lower leg. To achieve this, a search of electronic databases was first undertaken, followed by a description of characteristics of each study and critical appraisal of methods. Finally, a conclusion and recommendations for future studies is presented.

#### Search methods

A comprehensive search was conducted in the following databases: Google Scholar, Scopus (including ScienceDirect and PubMed), EBSCO (including Academic Search Complete, AMED, CINAHL, Health Source: Nursing/Academic Edition), MEDLINE and SPORTDiscus.

All full text article references were screened based on article title and abstract (figure 3). Articles that made reference to ‘ultrasound elastography reliability or feasibility’ in the title or abstract were saved. A composite list of articles that satisfied the following eligibility criteria was compiled: (1) the primary aim was to investigate *inter-rater* or *intra-rater* reliability of UES; (2) involvement of musculoskeletal structures of the leg (found between the knee and the foot); (3) article was published in English; and (4) performed *in vivo* on humans. Articles that met these criteria were analysed using the quality appraisal of reliability studies (‘QAREL’) tool (N. P. Lucas, Macaskill, Irwig, & Bogduk, 2010).

Figure 3. PRISMA flow chart of search strategy and study selection



## Search results

The results of the search are presented in figure 3. Thirteen studies were assessed for eligibility, six of these studies reported reliability data but did not meet the inclusion criteria and were excluded. Reasons for exclusion were: record was from a conference presentation published in abstract format rather than full-text (Kolt, 2013), reliability was not assessed on lower leg structures (Ahn et al., 2014; Lin, Lin, Chou, Chen, & Wang, 2015; Rios-Diaz et al., 2015), rather reliability was not the main focus of the study (Kesikburun et al., 2015; Mathevon et al., 2015). Thus, seven studies met the criteria for inclusion and were appraised using the QAREL checklist (Brandenburg et al., 2015; Chino et al., 2012; Dorado Cortez et al., 2015; Drakonaki et al., 2009; Dubois et al., 2015; Lacourpaille et al., 2012; N. Miyamoto et al., 2015).

Of the seven studies included in this review, six studies investigated the *intra*-rater reliability (Chino et al., 2012; Dorado Cortez et al., 2015; Drakonaki et al., 2009; Dubois et al., 2015; Lacourpaille et al., 2012; N. Miyamoto et al., 2015) for UES on a musculoskeletal structure of the leg using an *intra*-session repeatability study, except for Dubois et al.(2009) whose design was unclear (table 2). Five of the studies investigating *intra*-session reliability also studied the *inter*-rater reliability of UES in musculoskeletal structures (Chino et al., 2012; Dorado Cortez et al., 2015; Drakonaki et al., 2009; Dubois et al., 2015; Lacourpaille et al., 2015). Six studies conducted an *intra*-session design only (Brandenburg et al., 2015; Chino et al., 2012; Dorado Cortez et al., 2015; Drakonaki et al., 2009; Lacourpaille et al., 2012; N. Miyamoto et al., 2015), while two of these also performed *inter*-session analysis (Dorado Cortez et al., 2015; Lacourpaille et al., 2012). The design employed by Dubois et al. (2015) could not be ascertained because of poor quality of reporting and was therefore excluded.

Two studies investigated instrument reliability by using phantom tissue mimicking material in conjunction to human tissue analysis (Chino et al., 2012; N. Miyamoto et al., 2015). Only the human experiment of the study was analysed in this review.

	Rater			Participants		Design	Tissues studied	Elastography method	Results	Notes
	Number	Qualification	Experience	Number	Profile	Form of reliability				
Brandenburg et al (2014)	4	?	?	20	Asymptomatic children	Intra-session repeatability	Bilateral gastrocnemius at 4 ankle range	Shear-wave	mean (95% CI), 0.67 [range 0.44–0.83] to 0.80 [0.63–0.90])	Procedure unclear and ICC for raters not explained
Chino et al (2012)	2	? not specified	? not specified	-7 tissue mimicking material.		Inter and intra rater	- Tissue mimicking material.	Strain elastography	-ICC [1,1] was 0.99 [95% confidence interval (CI).	Two experiments. Intra rater reliability on tissue mimicking material and
				- 10 healthy	asymptomatic		- gastrocnemius medialis	Strain elastography	- ICC for rater1: 0.89 (95% CI, 0.78–0.95). -ICC for rater2: 0.77 (95% CI, 0.52–0.89) - Inter-rater ICC: 0.89 (95% CI, 0.78–0.95).	intra and inter rater reliability of Young modulus at different ankle position
Dorado-Cortez et al (2015)	2	radiologists	Rater1: 3 years Rater2: 7 years.	16	asymptomatic	Intra and inter operator	Tibialis anterior and gastrocnemius medialis	Shear-wave	<u>Longitudinal plane:</u> -Rater1-mean ICC: medial gastrocnemius: 0.70 (0.33- 0.88) and tibialis anterior: 0.42 (0- 0.75) -Rater2-mean ICC: medial gastrocnemius: 0.69 (0.31-0.88) and tibialis anterior: 0.70 (0.32- 0.88). -Inter-rater ICC: medial gastrocnemius: 0.73 (0.51- 0.86) Tibialis anterior: 0.69 (0.45- 0.83).	Five sites within each mm. each site was performed 3 times by each rater both longitudinal and transversely. Inter session 3weeks later.

									<u>Transverse plane:</u> -Rater1- ICC: Medial gastrocnemius: 0.57 ( 0.14- 0.82) and for tibialis anterior: 0.49 (0.00- 0.790) -Rater2- ICC: medial gastrocnemius: 0.39 (0- 0.73) ad for tibialis anterior: 0.45 (0- 0.77) Inter-rater ICC: medial gastrocnemius: 0.33 (0- 0.63) and for tibialis anterior: 0.21 ( 0- 0.55)	
Drakonaki et al (2009)	2	Radiologist	?	25	asymptomatic	Intra and inter observer	Bilateral Achilles tendon	Strain elastography	Longitudinal plane: -Rater1 ICC: 0.78 -Rater2 ICC: 0.66 -Inter-rater ICC: 0.51 Transverse plane: -Rater1 ICC: 0.43 -Rater2 ICC: 0.45 -Inter-rater ICC: 0.41	Tendons were examined in transverse and longitudinal plane
Dubois et al (2015)	Part 1: 3 Part 2: 2	? ?	? ?	10	asymptomatic	Part 1 & 2: Intra and inter operator	Vast. medialis and gastroc. lat, bicep fem., gracilis, rec. fem., sartorius, semimembranosus, soleus, semitendinosus.	Shear-wave	Part 1: -Inter- ICC stretch: 0.87- 0.90. -Inter- ICC rest: 0.88- 0.91 -Intra- ICC stretch: 0.92- 0.94 -Intra- ICC rest: 0.91- 0.92 Part 2: ?	ICC for part2 not reported
Lacourpaille et al (2012)	2	?	?	20= intra-session → intra-rater.	asymptomatic	Intra- and inter-session.	Gastroc med., tib. ant., vast. lat., rec.	Shear-wave	-Intra-rater, intra-session mean ICC: 0.871 ± 0.045 (range 0.811- 0.950).	

				21= inter-session. 16= inter-observer.		Inter – rater.	fem., tricep brac., bicep bra., brachiorad , adduct. poll. obli., abd. digit. min.		-Inter-session mean ICC: 0.815 ±0.065 (range 0.690- 0.922). -Inter-rater ICC ranged 0.421- 0.944	
Miyamoto et al (2015)	1	?	?	Part1= 7 tissue mimicking material		Intra and inter-session		Shear-wave	ICC for parallel and oblique test-retest and day to day= 1.00	Assess if the angle of the probe affected the shear modulus
				Part2= 11	asymptomatic		Bicep bra. and gastroc med.		ICC for parallel & oblique for bicep and gastro= 1.00	
Abbreviations: <i>gastroc lat</i> = gastrocnemius lateralis; <i>bicep fem.</i> = bicep femoris; <i>tib ant.</i> = tibialis anterior; <i>gastroc med.</i> = gastrocnemius medialis; <i>tricep bra.</i> = tricep brachii; <i>vast lat.</i> = vastus lateralis; <i>braciorad.</i> = brachiradialis; <i>adduct poll obli</i> = adductor pollicis oblique; <i>abd digit min.</i> = abductor digiti minimi; <i>vast medialis</i> = vastus medialis. ? = not reported										

## Quality assessment

The QAREL quality appraisal tool delineates 11 items essential to be reported in diagnostic test studies. Each item is equally weighted and is scored “yes”, “no”, or “unclear” and certain items can be rated as ‘Not Applicable’. The QAREL tool has been found to have acceptable rater reliability (N. Lucas et al., 2013). For the appraisal of the seven selected articles, Item 5 was not relevant because it involves blinding to the results of standard reference for the target disorder was excluded. Hence, all papers were scored out of a possible 10 items.

## Methodological issues identified in the studies reviewed

Results for quality appraisal of each study are reported in table 1. None of the studies included in this review scored above 5/10 in the QAREL, highlighting that these studies were at risk of methodological bias. Only two studies scored 5/10 (Dorado Cortez et al., 2015; Drakonaki et al., 2009) while the rest scored  $\leq 3/10$ . Results from the QAREL checklist reveal a great percentage of ‘unclear’ ratings arising from authors failing to report sufficient methodological detail. When appraising the seven studies of this review using the 10 applicable QAREL items, ‘unclear’ ratings were assigned to 64% of the total applicable ratings (49 of 76 rated items) and 53% of the ‘unclear’ rating (26/49) were related to blinding issues (table 1 QAREL Items 3, 4, 6, 7).

In addition to issues related to blinding, two main methodological weaknesses were apparent in the studies. Firstly, sample representativeness (QAREL item 1): the failure to report the inclusion and exclusion criteria for participation in the studies (5 of 7 studies) threaten a proper assessment of the applicability of the results (Blümle et al., 2011). Sampling selection should be strictly controlled to ensure that the selected sample represents the intended exposure population and failure to do so can lead to selection bias (Hernán, Hernández-Díaz, & Robins, 2004). Secondly, rater representativeness (QAREL item 2) was generally poor. Not all studies of this review reported the rater’s qualifications and expertise (only 2 of 7 studies adequately described their raters). It is essential that the rater sample is characterised as failure to do so may impact the reliability and agreement estimates (Kottner et al., 2011). Rater characteristics (e.g., qualifications, clinical background, knowledge, degree of expertise, and training) should be described on the grounds that they potentially can influence

results (Kobak, Lipsitz, Williams, Engelhardt, & Bellew, 2005) and such information is needed for later generalisation of results.

Table 1. Results of QAREL checklist												
QAREL item	1 Sample representative?	2 Raters representative?	3 Inter- raters Blinding ?	4 Intra- rater blinding ?	5 Blinding to standard reference	6 Blinding of clinical information?	7 Blinding to additional cues?	8 Order of examin- ation varied?	9 Time interval?	10 Test application and interpretation?	11 Appropriate statistical measure?	QAREL score
Brandenburg et al. (2014)	Y	?	?	?	N/A	?	?	N/A	?	N	N	1/8
Chino et al. (2012)	?	?	?	?	N/A	?	?	N/A	?	Y	Y	2/9
Dorado-Cortez et al. (2015)	?	Y	?	Y	N/A	?	?	?	Y	Y	Y	5/10
Drakonaki et al. (2009)	Y	Y	?	?	N/A	?	?	N/A	Y	Y	Y	5/9
Dubois et al. (2015)	?	?	?	?	N/A	?	?	?	?	N	Y	1/10
Lacourpaille et al. (2012)	?	?	?	?	N/A	?	?	?	Y	?	Y	1/10
Miyamoto et al. (2015)	?	?	N/A	?	N/A	?	?	?	?	Y	Y	2/10

Notes: Y = yes, N = No, N/A = Not applicable, ? = Unclear

Table 3. Reliability design					
	Intra-session	Inter-session	Intra-rater	Inter-rater	Instrument reliability
Brandenburg et al (2014)	✓				
Chino et al (2012)					
-tissue mimicking imaging	✓		✓		✓
-human gastrocnemius	✓		✓	✓	
Dorado- Cortez et al (2015)	✓	✓	✓	✓	
Drakonaki et al (2009)	✓		✓	✓	
Dubois et al (2015)	?	?	✓	✓	
Lacourpaille et al (2012)	✓	✓	✓	✓	
Miyamoto et al (2015)					
-tissue mimicking imaging	✓	✓	✓		✓
-human gastrocnemius	✓		✓		

### *Intra-rater reliability.*

*Intra-rater* reliability of UES was investigated in six studies, see table 2. Five of these studies investigated muscular structures of the leg (Chino et al., 2012; Dorado Cortez et al., 2015; Dubois et al., 2015; Lacourpaille et al., 2012; N. Miyamoto et al., 2015) while Drakonaki et al, (2009) was the only one investigating the Achilles tendon. Two of these studies used strain elastography (Chino et al., 2012; Drakonaki et al., 2009), and the remaining studies used shear-wave elastography. Although all studies assessing muscular tissue employed different study designs, and assessed the muscles stiffness at different positions and levels of tension, most found high intraclass correlation coefficients ( $ICC \geq 0.77$ ), except for Dorado Cortez et al. (2015), who identified ICC values ranging  $\geq 0.39$  to  $\leq 0.57$  when assessing the muscle with the probe in the transverse plane to the muscle fibres. For the Achilles tendon reliability ranged from  $ICC = 0.43$  to  $0.78$  (min-max) when assessed with the probe in the

longitudinal plane and ICC = 0.43 to 0.45 (min-max) when placed transversely (Drakonaki et al., 2009). Both Drakonaki et al. (2009) and Dorado Cortez et al. (2015) found that *intra-rater* reliability was better in the longitudinal plane than in the transverse plane.

#### *Inter-rater reliability.*

*Inter-rater* reliability of UES was investigated in 5 of the 7 studies analysed (K Chino et al., 2012; Dorado Cortez et al., 2015; Drakonaki et al., 2009; Dubois et al., 2015; Lilian Lacourpaille et al., 2012) (see table 3). Four of these assessed muscular structures while Drakonaki et al. (2009) assessed the Achilles tendon. *Inter-rater* reliability ICC values were substantially lower than *intra-rater* values (see table 2). The lowest reliability coefficients were found when assessing muscles with the probe positioned transversely to the muscle fibres (ICCs ranging from ICC 0.21 to 0.33) (Dorado Cortez et al., 2015). Lacourpaille et al. (2012) reported the widest ICCs range from 0.42 to 0.94 (min-max) and all studies reported reliability within this bracket. The reliability of UES for assessing the Achilles tendon were low, ranging from ICC = 0.51 (in the longitudinal plane) and ICC = 0.41 (in the transverse plane).

Brandenburg et al. (2015) performed an *intra-session* repeated measure study assessing muscle stiffness at different angles of dorsi and plantarflexion. Their mean reliability values ranged from ICC = 0.67 (95%CI 0.44 to 0.83) to 0.80 (95%CI 0.63 to 0.90). However, this study failed to consider the effect that different examiners could have on the measurement outcomes and ignored that time between measures was short and may have not been representative of what may be a typical interval between measures in clinical application.

#### Recommendations for future studies.

Despite the good level of reliability found in the studies reviewed, most were performed with methodological faults, especially regarding rater blinding. The limitations of reporting identified here highlight the need for further research to be conducted with better quality designs and improved reporting standards.

Furthermore, only two elastography techniques (strain and shear-wave elastography) were employed to assess the reliability of UES in musculoskeletal structures of the lower leg region.

Future studies employing other techniques such as ARFI on musculoskeletal structures should be undertaken. Given the poor quality of the studies which investigated the reliability of UES for the assessment of stiffness in soft tissue structures of the posterior lower leg, there is a rationale for a study to be undertaken with the aim of assessing the *intra*-operator and *inter*-operator reliability of UES using ARFI to assess the stiffness of the posterior aspect of the lower leg.

A study addressing this Aim is presented in the Section 2 of this thesis.

## REFERENCES

- Aboumarzouk, O. M., Ogston, S., Huang, Z., Evans, A., Melzer, A., Stolzenberg, J.-U., & Nabi, G. (2012). Diagnostic accuracy of transrectal elastosonography (TRES) imaging for the diagnosis of prostate cancer: a systematic review and meta-analysis. *BJU International*, *110*(10), 1414–23; discussion 1423. doi:10.1111/j.1464-410X.2012.11106.x
- Afdhal, N. H. (2012). Fibroscan (transient elastography) for the measurement of liver fibrosis. *Gastroenterology & Hepatology*, *8*(9), 605–7.
- Ahn, K. S., Kang, C. H., Hong, S. J., & Jeong, W. K. (2014). Ultrasound elastography of lateral epicondylitis: Clinical feasibility of quantitative elastographic measurements. *American Journal of Roentgenology*, *202*(5), 1094–1099. doi:10.2214/AJR.13.11003
- Akagi, R., Chino, K., Dohi, M., & Takahashi, H. (2012). Relationships between muscle size and hardness of the medial gastrocnemius at different ankle joint angles in young men. *Acta Radiologica*, *53*, 307–311. doi:10.1258/ar.2011.110481
- Akagi, R., & Takahashi, H. (2013). Acute effect of static stretching on hardness of the gastrocnemius muscle. *Medicine and Science in Sports and Exercise*, *45*(7), 1348–1354.
- Akagi, R., Yamashita, Y., & Ueyasu, Y. (2015). Age-Related Differences in Muscle Shear Moduli in the Lower Extremity. *Ultrasound in Medicine & Biology*, *41*(11), 2906–12. doi:10.1016/j.ultrasmedbio.2015.07.011
- Arda, K., Ciledag, N., Aktas, E., Aribas, B. K., & Köse, K. (2011). Quantitative assessment of normal soft-tissue elasticity using shear-wave ultrasound elastography. *AJR. American Journal of Roentgenology*, *197*(3), 532–6. doi:10.2214/AJR.10.5449
- Arya, S., & Kulig, K. (2010). Tendinopathy alters mechanical and material properties of the Achilles tendon. *Journal of Applied Physiology*, *108*(3), 670–675. doi:10.1152/jappphysiol.00259.2009
- Askeland, D., & Fulay, P. (2005). *The Science & Engineering of Materials*. Cengage Learning.
- Azizi, G., Keller, J. M., Mayo, M. L., Piper, K., Puett, D., Earp, K. M., & Malchoff, C. D. (2015). Thyroid Nodules and Shear Wave Elastography: A New Tool in Thyroid Cancer Detection. *Ultrasound in Medicine & Biology*, *41*(11), 2855–65. doi:10.1016/j.ultrasmedbio.2015.06.021
- Backman, L. J., & Danielson, P. (2011). Low range of ankle dorsiflexion predisposes for patellar tendinopathy in junior elite basketball players: a 1-year prospective study. *The American Journal of Sports Medicine*, *39*(12), 2626–33. doi:10.1177/0363546511420552
- Baddar, A., Granata, K., Damiano, D. L., Carmines, D. V., Blanco, J. S., & Abel, M. F. (2002). Ankle and knee coupling in patients with spastic diplegia: effects of gastrocnemius-soleus lengthening. *The Journal of Bone and Joint Surgery. American Volume*, *84-A*(5), 736–44.

- Badea, I., Tamas-Szora, A., Chiorean, I., Fildan, F., Ciuleanu, E., & Badea, M. (2014). Quantitative assessment of the masseter muscle's elasticity using Acoustic Radiation Force Impulse. *Medical Ultrasonography*, *16*(2), 89–94.
- Bahn, M. M., Brennan, M. D., Bahn, R. S., Dean, D. S., Kugel, J. L., & Ehman, R. L. (2009). Development and application of magnetic resonance elastography of the normal and pathological thyroid gland in vivo. *Journal of Magnetic Resonance Imaging*, *30*(5), 1151–1154. doi:10.1002/jmri.21963
- Bamber, J., Cosgrove, D., Dietrich, C. F., Fromageau, J., Bojunga, J., Calliada, F., ... Piscaglia, F. (2013). EFSUMB guidelines and recommendations on the clinical use of ultrasound elastography. Part 1: Basic principles and technology. *Ultraschall in Der Medizin (Stuttgart, Germany : 1980)*, *34*(2), 169–84. doi:10.1055/s-0033-1335205
- Barr, R. G. (2012). Elastography in evaluation of musculoskeletal abnormalities. *Applied Radiology*, *41*(12), 53–55.
- Barr, R. G., Memo, R., & Schaub, C. R. (2012). Shear Wave Ultrasound Elastography of the Prostate. *Ultrasound Quarterly*, *28*(1), 13–20. doi:10.1097/RUQ.0b013e318249f594
- Baumgart, F. (2000). Stiffness — an unknown world of mechanical science? *Injury*, *31*, 14–84. doi:10.1016/S0020-1383(00)80040-6
- Bencardino, J. T., Rosenberg, Z. S., Brown, R. R., Hassankhani, A., Lustrin, E. S., & Beltran, J. (2000). Traumatic musculotendinous injuries of the knee: diagnosis with MR imaging. *Radiographics : A Review Publication of the Radiological Society of North America, Inc.*, *20 Spec No*, S103–20. doi:10.1148/radiographics.20.suppl\_1.g00oc16s103
- Benetazzo, L., Bizzego, A., De Caro, R., Frigo, G., Guidolin, D., & Stecco, C. (2011). 3D reconstruction of the crural and thoracolumbar fasciae. *Surgical and Radiologic Anatomy*, *33*(10), 855–862. doi:10.1007/s00276-010-0757-7
- Bensamoun, S. F., Ringleb, S. I., Littrell, L., Chen, Q., Brennan, M., Ehman, R. L., & An, K. N. (2006). Determination of thigh muscle stiffness using magnetic resonance elastography. *Journal of Magnetic Resonance Imaging*, *23*(2), 242–247. doi:10.1002/jmri.20487
- Bentman, S., O'Sullivan, C., & Stokes, M. (2010). Thickness of the middle trapezius muscle measured by rehabilitative ultrasound imaging: description of the technique and reliability study. *Clinical Physiology & Functional Imaging*, *30*(6), 426–431. doi:10.1111/j.1475-097X.2010.00960.x
- Blümle, A., Meerpohl, J. J., Rucker, G., Antes, G., Schumacher, M., & von Elm, E. (2011). Reporting of eligibility criteria of randomised trials: cohort study comparing trial protocols with subsequent articles. *BMJ*, *342*, d1828. doi:10.1136/bmj.d1828
- Bob, F., Bota, S., Sporea, I., Sirli, R., Petrica, L., & Schiller, A. (2014). Kidney Shear Wave Speed Values in Subjects with and without Renal Pathology and Inter-Operator Reproducibility of Acoustic Radiation Force Impulse Elastography (ARFI) - Preliminary Results. *PloS One*, *9*(11), e113761. doi:10.1371/journal.pone.0113761

- Bojunga, J., Herrmann, E., Meyer, G., Weber, S., Zeuzem, S., & Friedrich-Rust, M. (2010). Real-time elastography for the differentiation of benign and malignant thyroid nodules: a meta-analysis. *Thyroid*, *20*(10), 1145–50. doi:10.1089/thy.2010.0079
- Bota, S., Herkner, H., Sporea, I., Salzl, P., Sirli, R., Neghina, A. M., & Peck-Radosavljevic, M. (2013). Meta-analysis: ARFI elastography versus transient elastography for the evaluation of liver fibrosis. *Liver International*, *33*(8), 1138–47. doi:10.1111/liv.12240
- Botar-jid, C., Damian, L., Dudea, S. M., Vasilescu, D., & Rednic, S. (2010). The contribution of ultrasonography and sonoelastography in assessment of myositis. *Medical Ultrasonography*, *12*(2), 120–126.
- Botar-Jid, C., Damian, L., Dudea, S. M., Vasilescu, D., Rednic, S., & Radu Badea. (2010). The contribution of ultrasonography and sonoelastography in assessment of myositis. *Medical Ultrasonography*.
- Bouillard, K., Jubeau, M., Nordez, A., & Hug, F. (2014). Effect of vastus lateralis fatigue on load sharing between quadriceps femoris muscles during isometric knee extensions. *Journal of Neurophysiology*, *111*(4), 768–76. doi:10.1152/jn.00595.2013
- Bouillard, K., Nordez, A., & Hug, F. (2011). Estimation of individual muscle force using elastography. *PLoS One*, *6*(12), e29261. doi:10.1371/journal.pone.0029261
- Brandenburg, J. E., Eby, S. F., Song, P., Zhao, H., Brault, J. S., Chen, S., & An, K.-N. (2014). Ultrasound Elastography: The New Frontier in Direct Measurement of Muscle Stiffness. *Archives of Physical Medicine and Rehabilitation*, *95*(11), 2207–19. doi:10.1016/j.apmr.2014.07.007
- Brandenburg, J. E., Eby, S. F., Song, P., Zhao, H., Landry, B. W., Kingsley-Berg, S., ... Kai-Nan, A. (2015). Feasibility and Reliability of Quantifying Passive Muscle Stiffness in Young Children by Using Shear Wave Ultrasound Elastography. *Journal of Ultrasound in Medicine*, *34*(4), 663–670. doi:10.7863/ultra.34.4.663
- Brown, P. G., Alsousou, J., Cooper, A., Thompson, M. S., & Noble, J. A. (2013). The AutoQual ultrasound elastography method for quantitative assessment of lateral strain in post-rupture Achilles tendons. *J Biomech*, *46*(15), 2695–2700. doi:10.1016/j.jbiomech.2013.07.044
- Brum, J., Bernal, M., Gennisson, J. L., & Tanter, M. (2014). In vivo evaluation of the elastic anisotropy of the human Achilles tendon using shear wave dispersion analysis. *Physics in Medicine and Biology*, *59*(3), 505–23. doi:10.1088/0031-9155/59/3/505
- Bryan Dixon, J. (2009). Gastrocnemius vs. soleus strain: how to differentiate and deal with calf muscle injuries. *Current Reviews in Musculoskeletal Medicine*, *2*(2), 74–77. doi:10.1007/s12178-009-9045-8
- Butler, D. L., Grood, E. S., Noyes, F. R., & Zernicke, R. F. (1978). Biomechanics of ligaments and tendons. *Exercise and Sport Sciences Reviews*, *6*, 125–81.
- Butler, J. V., Mulkerrin, E. C., & O’Keeffe, S. T. (2002). Nocturnal leg cramps in older people. *Postgraduate Medical Journal*, *78*(924), 596–598. doi:10.1136/pmj.78.924.596

- Calancie, B., & Stein, R. B. (1987). Measurement of rate constants for the contractile cycle of intact mammalian muscle fibers. *Biophysical Journal*, *51*(2), 149–59. doi:10.1016/S0006-3495(87)83320-9
- Campbell, J. T. (2009). Posterior calf injury. *Foot and Ankle Clinics*, *14*(4), 761–71. doi:10.1016/j.fcl.2009.07.005
- Carlsen, J., Ewertsen, C., Lönn, L., & Nielsen, M. (2013). Strain Elastography Ultrasound: An Overview with Emphasis on Breast Cancer Diagnosis. *Diagnostics*, *3*(1), 117–125. doi:10.3390/diagnostics3010117
- Carlsen, J., Ewertsen, C., Săftoiu, A., Lönn, L., & Nielsen, M. B. (2014). Accuracy of Visual Scoring and Semi-Quantification of Ultrasound Strain Elastography – A Phantom Study. *PLoS One*, *9*(2), e88699. doi:10.1371/journal.pone.0088699
- Chaitow, L. (1997). Soft tissue manipulation: Assessment and treatment methods for musculoskeletal pain and dysfunction. *International Journal of Aromatherapy*, *8*(3), 21–27.
- Chang, J. M., Won, J.-K., Lee, K.-B., Park, I. A., Yi, A., & Moon, W. K. (2013). Comparison of shear-wave and strain ultrasound elastography in the differentiation of benign and malignant breast lesions. *American Journal of Roentgenology*, *201*(2), W347–56. doi:10.2214/AJR.12.10416
- Chen, Q., Bensamoun, S., Basford, J. R., Thompson, J. M., & An, K. N. (2007). Identification and Quantification of Myofascial Taut Bands With Magnetic Resonance Elastography. *Archives of Physical Medicine and Rehabilitation*, *88*(12), 1658–1661. doi:10.1016/j.apmr.2007.07.020
- Chen, X.-M., Cui, L.-G., He, P., Shen, W.-W., Qian, Y.-J., & Wang, J.-R. (2013). Shear wave elastographic characterization of normal and torn achilles tendons: a pilot study. *Journal of Ultrasound in Medicine*, *32*(3), 449–55.
- Chila, A. G., & American Osteopathic Association. (2011). *Foundations of Osteopathic Medicine*. Philadelphia: Wolters Kluwer Health/Lippincott Williams & Wilkins .
- Chino, K., Akagi, R., Dohi, M., Fukashiro, S., & Takahashi, H. (2012). Reliability and validity of quantifying absolute muscle hardness using ultrasound elastography. *PLoS One*, *7*(9), e45764. doi:10.1371/journal.pone.0045764
- Chino, K., Akagi, R., Dohi, M., & Takahashi, H. (2013). Measurement of muscle architecture concurrently with muscle hardness using ultrasound strain elastography. *Acta Radiol*, *55*(7), 833–839. doi:10.1177/0284185113507565
- Chiou, H.-J., Chou, Y.-H., Chiou, S.-Y., Liu, J.-B., & Chang, C.-Y. (2003). Peripheral Nerve Lesions: Role of High-Resolution US. *Radiographics*, *23*(6). doi:10.1148/rg.e15
- Cho, K. H., & Nam, J. H. (2015). Evaluation of stiffness of the spastic lower extremity muscles in early spinal cord injury by acoustic radiation force impulse imaging. *Annals of Rehabilitation Medicine*, *39*(3), 393–400. doi:10.5535/arm.2015.39.3.393
- Cohen, J. C. (2009). Anatomy and Biomechanical Aspects of the Gastrocnemius Complex. *Foot and Ankle Clinics*, *14*(4), 617–626. doi:10.1016/j.fcl.2009.08.006

- Comeaux, Z. (2001). Palpatory accuracy: time to reflect. *Journal of Bodywork and Movement Therapies*, 5(4), 223–226. doi:10.1054/jbmt.2001.0240
- Comeaux, Z., Eland, D., Chila, A., Pheley, A., & Tate, M. (2001). Measurement challenges in physical diagnosis: refining inter-rater palpation, perception and communication. *Journal of Bodywork and Movement Therapies*, 5(4), 245–253. doi:10.1054/jbmt.2001.0236
- Comerford, M. J., & Mottram, S. L. (2001). Functional stability re-training: principles and strategies for managing mechanical dysfunction. *Manual Therapy*, 6(1), 3–14. doi:10.1054/math.2000.0389
- Coqueiro, K. R. R., Bevilaqua-Grossi, D., Bérzin, F., Soares, A. B., Candolo, C., & Monteiro-Pedro, V. (2005). Analysis on the activation of the VMO and VLL muscles during semisquat exercises with and without hip adduction in individuals with patellofemoral pain syndrome. *Journal of Electromyography and Kinesiology*, 15(6), 596–603. doi:10.1016/j.jelekin.2005.03.001
- Correas, J.-M., Drakonakis, E., Isidori, A. M., Helenon, O., Pozza, C., Cantisani, V., ... D'Ambrosio, F. (2013). Update on ultrasound elastography: miscellanea. Prostate, testicle, musculo-skeletal. *European Journal of Radiology*, 82(11), 1904–1912. doi:10.1016/j.ejrad.2013.05.031
- Cosgrove, D., Piscaglia, F., Bamber, J., Bojunga, J., Correas, J. M., Gilja, O. H., ... Dietrich, C. F. (2013). EFSUMB Guidelines and Recommendations on the clinical use of ultrasound elastography part 2: Clinical applications. *Ultraschall in Der Medizin*, 34(3), 238–253. doi:10.1055/s-0033-1335375
- Counsel, P., & Bredahl, W. (2010). Muscle injuries of the lower leg. *Seminars in Musculoskeletal Radiology*, 14(2), 162–75. doi:10.1055/s-0030-1253158
- Crommert, M. E., Lacourpaille, L., Heales, L. J., Tucker, K., & Hug, F. (2015). Massage induces an immediate, albeit short-term, reduction in muscle stiffness. *Scandinavian Journal of Medicine and Science in Sports*, 25(5), e490–e496. doi:10.1111/sms.12341
- Davies, E. L. (2014). *Reliability of crural fascia and Achilles tendon excursion using ultrasound imaging : A pilot study*. Master thesis. Unitec Institute of Technology. Auckland, New Zealand.
- De Zordo, T., Chhem, R., Smekal, V., Feuchtner, G., Reindl, M., Fink, C., ... Klauser, A. S. (2010). Real-time sonoelastography: Findings in patients with symptomatic achilles tendons and comparison to healthy volunteers. *Ultraschall in Der Medizin*, 31(4), 394–400. doi:10.1055/s-0028-1109809
- De Zordo, T., Fink, C., Feuchtner, G. M., Smekal, V., Reindl, M., & Klauser, A. S. (2009). Real-Time Sonoelastography Findings in Healthy Achilles Tendons. *American Journal of Roentgenology*, 193(2), W134–W138. doi:10.2214/AJR.08.1843
- De Zordo, T., Lill, S. R., Fink, C., Feuchtner, G. M., Jaschke, W., Bellmann-Weiler, R., & Klauser, A. S. (2009). Real-time sonoelastography of lateral epicondylitis: comparison of findings between patients and healthy volunteers. *AJR. American Journal of Roentgenology*, 193(1), 180–5. doi:10.2214/AJR.08.2020
- DiGiovanni, C. W., Kuo, R., Tejwani, N., Price, R., Hansen, S. T., Czierniecki, J., & Sangeorzan, B. J. (2002). Isolated gastrocnemius tightness. *The Journal of Bone & Joint Surgery*, 84-A(August 2015).

- Dorado Cortez, C., Hermitte, L., Romain, A., Mesmann, C., Lefort, T., & Pialat, J. B. (2015). Ultrasound shear wave velocity in skeletal muscle: A reproducibility study. *Diagnostic and Interventional Imaging*. doi:10.1016/j.diii.2015.05.010
- Drakonaki, E. E., & Allen, G. M. (2010). Magnetic resonance imaging, ultrasound and real-time ultrasound elastography of the thigh muscles in congenital muscle dystrophy. *Skeletal Radiology*, 39(4), 391–396. doi:10.1007/s00256-009-0861-0
- Drakonaki, E. E., Allen, G. M., & Wilson, D. J. (2009). Real-time ultrasound elastography of the normal Achilles tendon: reproducibility and pattern description. *Clinical Radiology*, 64(12), 1196–1202. doi:10.1016/j.crad.2009.08.006
- Drakonaki, E. E., Allen, G. M., & Wilson, D. J. (2012). Ultrasound elastography for musculoskeletal applications. *British Journal of Radiology*, 85(1019), 1435–1445. doi:10.1259/bjr/93042867
- Dubois, G., Kheireddine, W., Vergari, C., Bonneau, D., Thoreux, P., Rouch, P., ... Skalli, W. (2015). Reliable Protocol for Shear Wave Elastography of Lower Limb Muscles at Rest and During Passive Stretching. *Ultrasound in Medicine & Biology*, 1–8. doi:10.1016/j.ultrasmedbio.2015.04.020
- Eby, S. F., Cloud, B. a., Brandenburg, J. E., Giambini, H., Song, P., Chen, S., ... An, K.-N. (2015a). Shear wave elastography of passive skeletal muscle stiffness: Influences of sex and age throughout adulthood. *Clinical Biomechanics*, 30(1), 22–27. doi:10.1016/j.clinbiomech.2014.11.011
- Eby, S. F., Cloud, B. A., Brandenburg, J. E., Giambini, H., Song, P., Chen, S., ... An, K.-N. (2015b). Shear wave elastography of passive skeletal muscle stiffness: influences of sex and age throughout adulthood. *Clinical Biomechanics (Bristol, Avon)*, 30(1), 22–7. doi:10.1016/j.clinbiomech.2014.11.011
- EL-Hariri, M. A., Taha Ali, T. F., Tawab, M. A., Magid, A. M. A., & EL-Shiekh, A.-F. (2014). The clinical value of ultrasound elastography in predicting malignant thyroid nodules. *The Egyptian Journal of Radiology and Nuclear Medicine*, 45(2), 353–359. doi:10.1016/j.ejrm.2014.03.006
- Ellis, R., Hing, W., Dille, A., & McNair, P. (2008). Reliability of Measuring Sciatic and Tibial Nerve Movement with Diagnostic Ultrasound During a Neural Mobilisation Technique. *Ultrasound in Medicine and Biology*, 34(8), 1209–1216. doi:10.1016/j.ultrasmedbio.2008.01.003
- Emery, A. E. H. (2002). The muscular dystrophies. *The Lancet*, 359, 687–695. doi:10.1016/S0140-6736(02)07815-7
- Ferraioli, G., Parekh, P., Levitov, A. B., & Filice, C. (2014). Shear Wave Elastography for Evaluation of Liver Fibrosis. *Journal of Ultrasound in Medicine*, 33(2), 197–203. doi:10.7863/ultra.33.2.197
- Ferreira, P. H., Ferreira, M. L., & Hodges, P. W. (2004). Changes in Recruitment of the Abdominal Muscles in People With Low Back Pain. *Spine*, 29(22), 2560–2566. doi:10.1097/01.brs.0000144410.89182.f9
- Fraquelli, M., Rigamonti, C., Casazza, G., Conte, D., Donato, M. F., Ronchi, G., & Colombo, M. (2007). Reproducibility of transient elastography in the evaluation of liver fibrosis in patients with chronic liver disease. *Gut*, 56(7), 968–73. doi:10.1136/gut.2006.111302

- Friedrich-Rust, M., Wunder, K., Kriener, S., Sotoudeh, F., Richter, S., Bojunga, J., ... Sarrazin, C. (2009). Liver fibrosis in viral hepatitis: noninvasive assessment with acoustic radiation force impulse imaging versus transient elastography. *Radiology*, 252(2), 595–604. doi:252/2/595 [pii]n10.1148/radiol.2523081928
- Frink, M., Hildebrand, F., Krettek, C., Brand, J., & Hankemeier, S. (2010). Compartment syndrome of the lower leg and foot. *Clinical Orthopaedics and Related Research*, 468(4), 940–50. doi:10.1007/s11999-009-0891-x
- Fung, Y.-C. (2013). *Biomechanics: mechanical properties of living tissues*. Springer Science & Business Media.
- Gallo, R. A., Plakke, M., & Silvis, M. L. (2012). Common Leg Injuries of Long-Distance Runners: Anatomical and Biomechanical Approach. *Sports Health: A Multidisciplinary Approach*, 4(6), 485–495. doi:10.1177/1941738112445871
- Garra, B. S. (2011). Elastography: current status, future prospects, and making it work for you. *Ultrasound Quarterly*, 27(3), 177–86. doi:10.1097/RUQ.0b013e31822a2138
- Gennisson, J.-L., Catheline, S., Chaffai, S., & Fink, M. (2003). Transient elastography in anisotropic medium: application to the measurement of slow and fast shear wave speeds in muscles. *The Journal of the Acoustical Society of America*, 114(1), 536–541. doi:10.1121/1.1579008
- Gennisson, J.-L., Cornu, C., Catheline, S., Fink, M., & Portero, P. (2005). Human muscle hardness assessment during incremental isometric contraction using transient elastography. *Journal of Biomechanics*, 38(7), 1543–1550. doi:10.1016/j.jbiomech.2004.07.013
- Gennisson, J.-L., Deffieux, T., Fink, M., & Tanter, M. (2013). Ultrasound elastography: Principles and techniques. *Diagnostic and Interventional Imaging*, (94), 487–495.
- Gheonea, D. I., Săftoiu, A., Ciurea, T., Gorunescu, F., Iordache, S., Popescu, G. L., ... Săndulescu, L. (2010). Real-time sono-elastography in the diagnosis of diffuse liver diseases. *World Journal of Gastroenterology*, 16(14), 1720–1726. doi:10.3748/wjg.v16.i14.1720
- Given, J. D., Dewald, J. P., & Rymer, W. Z. (1995). Joint dependent passive stiffness in paretic and contralateral limbs of spastic patients with hemiparetic stroke. *Journal of Neurology, Neurosurgery, and Psychiatry*, 59(3), 271–279. doi:10.1136/jnnp.59.3.271
- Goddi, A., Bonardi, M., & Alessi, S. (2012). Breast elastography: A literature review. *Journal of Ultrasound*, 15(3), 192–8. doi:10.1016/j.jus.2012.06.009
- Gonçalves, B., Soares, J. B., & Bastos, P. (2015). Endoscopic Ultrasound in the Diagnosis and Staging of Pancreatic Cancer. *GE Portuguese Journal of Gastroenterology*, 22(4), c. doi:10.1016/j.jpge.2015.04.007
- Gong, X., Xu, Q., Xu, Z., Xiong, P., Yan, W., & Chen, Y. (2011). Real-time elastography for the differentiation of benign and malignant breast lesions: a meta-analysis. *Breast Cancer Research and Treatment*, 130(1), 11–8. doi:10.1007/s10549-011-1745-2
- Haneline, M. T., & Young, M. (2009). A Review of Intraexaminer and Interexaminer Reliability of Static Spinal Palpation: A Literature Synthesis. *Journal of Manipulative and Physiological Therapeutics*, 32(5), 379–386. doi:10.1016/j.jmpt.2009.04.010

- Havre, R. F., Waage, J. R., Gilja, O. H., Odegaard, S., & Nesje, L. B. (2011). Real-Time Elastography: Strain Ratio Measurements Are Influenced by the Position of the Reference Area. *Ultraschall in Der Medizin (Stuttgart, Germany : 1980)*, (January 2016). doi:10.1055/s-0031-1273247
- Hernán, M. A., Hernández-Díaz, S., & Robins, J. M. (2004). A Structural Approach to Selection Bias. *Epidemiology*, 15(5), 615–625. doi:10.1097/01.ede.0000135174.63482.43
- Hertling, D., & Kessler, R. M. (2006). *Management of common musculoskeletal disorders: physical therapy principles and methods*. Lippincott Williams & Wilkins.
- Hopper, D., Deacon, S., Das, S., Jain, A., Riddell, D., Hall, T., & Briffa, K. (2005). Dynamic soft tissue mobilisation increases hamstring flexibility in healthy male subjects. *British Journal of Sports Medicine*, 39(9), 594–8; discussion 598. doi:10.1136/bjsm.2004.011981
- Hug, F., Tucker, K., Gennisson, J.-L., Tanter, M., & Nordez, A. (2015). Elastography for Muscle Biomechanics. *Exercise and Sport Sciences Reviews*, (38), 1. doi:10.1249/JES.0000000000000049
- Hughes, L. Y. (1985). Biomechanical Analysis of the Foot and Ankle for Predisposition to Developing Stress Fractures. *Journal of Orthopaedic & Sports Physical Therapy*, 7(3), 96–101. doi:10.2519/jospt.1985.7.3.96
- Itoh, A., Ueno, E., Tohno, E., Kamma, H., Takahashi, H., Shiina, T., ... Matsumura, T. (2006). Breast disease: clinical application of US elastography for diagnosis. *Radiology*, 239(2), 341–350. doi:10.1148/radiol.2391041676
- Jan Ekstrand, Martin Hägglund, & Markus Waldén. (2011). Epidemiology of Muscle Injuries in Professional Football ( Soccer ). *American Journal of Sports Medicine*, 1–7. doi:10.1177/0363546510395879
- Jeong, W. K., Lim, H. K., Lee, H.-K., Jo, J. M., & Kim, Y. (2014). Principles and clinical application of ultrasound elastography for diffuse liver disease. *Ultrasonography*, 33(3), 149–160. doi:2014.33.3.149
- Joseph, M. F., Lillie, K. R., Bergeron, D. J., & Denegar, C. R. (2012). Measuring Achilles Tendon Mechanical Properties: A Reliable, Noninvasive Method. *Journal of Strength & Conditioning Research*, 26(8), 2017–2020. doi:10.1519/JSC.0b013e31825bb47f
- Kaufman, K. R., Brodine, S. K., Shaffer, R. A., Johnson, C. W., & Cullison, T. R. (1999). The Effect of Foot Structure and Range of Motion on Musculoskeletal Overuse Injuries. *The American Journal of Sports Medicine*, 27(5), 585–593.
- Kesikburun, S., Yaşar, E., Adıgüzel, E., Güzelküçük, Ü., Alaca, R., & Tan, A. K. (2015). Assessment of Spasticity With Sonoelastography Following Stroke: A Feasibility Study. *PM & R : The Journal of Injury, Function, and Rehabilitation*. doi:10.1016/j.pmrj.2015.05.019
- Klauser, A. S., Faschingbauer, R., & Jaschke, W. R. (2010). Is sonoelastography of value in assessing tendons? *Seminars in Musculoskeletal Radiology*, 14(3), 323–333. doi:10.1055/s-0030-1254521
- Kobak, K. A., Lipsitz, J. D., Williams, J. B. W., Engelhardt, N., & Bellew, K. M. (2005). A new approach to rater training and certification in a multicenter clinical trial. *Journal of Clinical Psychopharmacology*, 25(5), 407–12.

- Kolipaka, A., Araoz, P. A., McGee, K. P., Manduca, A., & Ehman, R. L. (2010). Magnetic resonance elastography as a method for the assessment of effective myocardial stiffness throughout the cardiac cycle. *Magnetic Resonance in Medicine*, *64*(3), 862–870. doi:10.1002/mrm.22467
- Kolt, G. S. (2013). The risky side of sports participation. *Journal of Science and Medicine in Sport / Sports Medicine Australia*, *16*(2), 87–8. doi:10.1016/j.jsams.2013.01.003
- Koppenhaver, S. L., Hebert, J. J., Fritz, J. M., Parent, E. C., Teyhen, D. S., & Magel, J. S. (2009). Reliability of rehabilitative ultrasound imaging of the transversus abdominis and lumbar multifidus muscles. *Archives of Physical Medicine and Rehabilitation*, *90*(1), 87–94. doi:10.1016/j.apmr.2008.06.022
- Kot, B. C. W., Zhang, Z. J., Lee, A. W. C., Leung, V. Y. F., & Fu, S. N. (2012). Elastic modulus of muscle and tendon with shear wave ultrasound elastography: variations with different technical settings. *PLoS One*, *7*(8), e44348. doi:10.1371/journal.pone.0044348
- Kottner, J., Audige, L., Brorson, S., Donner, A., Gajewski, B. J., Hróbjartsson, A., ... Streiner, D. L. (2011). Guidelines for Reporting Reliability and Agreement Studies (GRRAS) were proposed. *International Journal of Nursing Studies*, *48*(6), 661–671. doi:10.1016/j.ijnurstu.2011.01.016
- Krouskop, T. A., Wheeler, T. M., Kallel, F., Garra, B. S., & Hall, T. (1998). Elastic Moduli of Breast and Prostate Tissues under Compression. *Ultrasonic Imaging*, *20*(4), 260–274. doi:10.1177/016173469802000403
- Kruse, S. A., Rose, G. H., Glaser, K. J., Manduca, A., Felmlee, J. P., Jack, C. R., & Ehman, R. L. (2008). Magnetic resonance elastography of the brain. *NeuroImage*, *39*(1), 231–237. doi:10.1016/j.neuroimage.2007.08.030
- Kubo, K., Kanehisa, H., & Fukunaga, T. (2002). Effects of resistance and stretching training programmes on the viscoelastic properties of human tendon structures in vivo. *The Journal of Physiology*, *538*(Pt 1), 219–226. doi:10.1113/jphysiol.2001.012703
- Kubo, K., Kanehisa, H., & Fukunaga, T. (2003). Gender differences in the viscoelastic properties of tendon structures. *European Journal of Applied Physiology*, *88*(6), 520–526. doi:10.1007/s00421-002-0744-8
- Kuo, W.-H., Jian, D.-W., Wang, T.-G., & Wang, Y.-C. (2013). Neck muscle stiffness quantified by sonoelastography is correlated with body mass index and chronic neck pain symptoms. *Ultrasound in Medicine & Biology*, *39*(8), 1356–61. doi:10.1016/j.ultras medbio.2012.11.015
- Lacourpaille, L., Hug, F., Bouillard, K., Hogrel, J.-Y., & Nordez, A. (2012). Supersonic shear imaging provides a reliable measurement of resting muscle shear elastic modulus. *Physiological Measurement*, *33*(3), N19–N28. doi:10.1088/0967-3334/33/3/N19
- Lacourpaille, L., Hug, F., Guével, A., Péréon, Y., Magot, A., Hogrel, J.-Y., & Nordez, A. (2015). Non-invasive assessment of muscle stiffness in patients with Duchenne muscular dystrophy. *Muscle & Nerve*, *51*(2), 284–6. doi:10.1002/mus.24445
- Lacourpaille, L., Nordez, A., Hug, F., Couturier, A., Dibie, C., & Guilhem, G. (2014). Time-course effect of exercise-induced muscle damage on localized muscle mechanical properties assessed using elastography. *Acta Physiologica (Oxford, England)*, *211*(1), 135–46. doi:10.1111/apha.12272

- Lalitha, P., Reddy, Mc., & Reddy, K. J. (2011). Musculoskeletal applications of elastography: a pictorial essay of our initial experience. *Korean J Radiol*, *12*(3), 365–375. doi:10.3348/kjr.2011.12.3.365
- Langevin, H. M., Fox, J. R., Koptiuch, C., Badger, G. J., Greenan-Naumann, A. C., Bouffard, N. A., ... Henry, S. M. (2011). Reduced thoracolumbar fascia shear strain in human chronic low back pain. *BMC Musculoskeletal Disorders*, *12*(203). doi:10.1186/1471-2474-12-203
- Li, Y., & Snedeker, J. G. (2011). Elastography: Modality-specific approaches, clinical applications, and research horizons. *Skeletal Radiology*, *40*(4), 389–397. doi:10.1007/s00256-010-0918-0
- Liebenson, C. (2007). *Rehabilitation of the Spine: A Practitioner's Manual*. (C. Liebenson, Ed.) (Second.). Lippincott Williams & Wilkins.
- Lin, C.-Y., Lin, C.-C., Chou, Y.-C., Chen, P.-Y., & Wang, C.-L. (2015). Heel Pad Stiffness in Plantar Heel Pain by Shear Wave Elastography. *Ultrasound in Medicine & Biology*, *41*(11), 2890–2898. doi:10.1016/j.ultras medbio.2015.07.004
- Liu, B., Zheng, Y., Shan, Q., Lu, Y., Lin, M., Tian, W., & Xie, X. (2015). Elastography by acoustic radiation force impulse technology for differentiation of benign and malignant breast lesions: a meta-analysis. *Journal of Medical Ultrasonics*, *43*(1), 47–55. doi:10.1007/s10396-015-0658-9
- Liu, B.-J., Li, D.-D., Xu, H.-X., Guo, L.-H., Zhang, Y.-F., Xu, J.-M., ... Xing, M. (2015). Quantitative Shear Wave Velocity Measurement on Acoustic Radiation Force Impulse Elastography for Differential Diagnosis between Benign and Malignant Thyroid Nodules: A Meta-analysis. *Ultrasound in Medicine & Biology*, *41*(12), 3035–43. doi:10.1016/j.ultras medbio.2015.08.003
- Lucas, N., Macaskill, P., Irwig, L., Moran, R., & Bogduk, N. (2009). Reliability of physical examination for diagnosis of myofascial trigger points: a systematic review of the literature. *The Clinical Journal of Pain*, *25*(1), 80–9. doi:10.1097/AJP.0b013e31817e13b6
- Lucas, N., Macaskill, P., Irwig, L., Moran, R., Rickards, L., Turner, R., & Bogduk, N. (2013). The reliability of a quality appraisal tool for studies of diagnostic reliability (QAREL). *BMC Medical Research Methodology*, *13*, 111. doi:10.1186/1471-2288-13-111
- Lucas, N. P., Macaskill, P., Irwig, L., & Bogduk, N. (2010). The development of a quality appraisal tool for studies of diagnostic reliability (QAREL). *Journal of Clinical Epidemiology*, *63*(8), 854–861. doi:10.1016/j.jclinepi.2009.10.002
- Luomala, T., Pihlman, M., Heiskanen, J., & Stecco, C. (2014). Case study: Could ultrasound and elastography visualized densified areas inside the deep fascia? *Journal of Bodywork and Movement Therapies*, *18*(3), 462–468. doi:10.1016/j.jbmt.2013.11.020
- Mac Donald, D., Wan, A., Mc Phee, M., Tucker, K., & Hug, F. (2015). Reliability of Abdominal Muscle Stiffness Measured using elastography during trunk rehabilitation exercises. *Ultrasound in Medicine & Biology*, *In-Press*, 1–8.
- Mahieu, N. N., Witvrouw, E., Stevens, V., Van Tiggelen, D., & Roget, P. (2006). Intrinsic risk factors for the development of achilles tendon overuse injury: a prospective study. *The American Journal of Sports Medicine*, *34*(2), 226–35. doi:10.1177/0363546505279918

- Manduca, A., Oliphant, T. E., Dresner, M. A., Mahowald, J. L., Kruse, S. A., Amromin, E., ... Ehman, R. L. (2001). Magnetic resonance elastography: Non-invasive mapping of tissue elasticity. *Medical Image Analysis*, 5(4), 237–254. doi:10.1016/S1361-8415(00)00039-6
- Mariappan, Y. K., Glaser, K. J., & Ehman, R. L. (2010). Magnetic resonance elastography: a review. *Clinical Anatomy (New York, N.Y.)*, 23(5), 497–511. doi:10.1002/ca.21006
- Mathevon, L., Michel, F., Aubry, S., Testa, R., Lapole, T., Boulard, C., ... Calmels, P. (2015). Reliability of 2D ultrasound imaging associated with transient ShearWave Elastography method to analyze spastic gastrocnemius medialis muscle architecture and viscoelastic properties. *Annals of Physical and Rehabilitation Medicine*, 58, e75. doi:10.1016/j.rehab.2015.07.184
- McKay, G. D., Goldie, P. a, Payne, W. R., & Oakes, B. W. (2001). Ankle injuries in basketball: injury rate and risk factors. *British Journal of Sports Medicine*, 35(2), 103–108. doi:10.1136/bjsm.35.2.103
- McKiernan, S., Chiarelli, P., & Warren-Forward, H. (2013). Professional issues in the use of diagnostic ultrasound biofeedback in physiotherapy of the female pelvic floor. *Radiography*, 19(2), 117–124. doi:10.1016/j.radi.2013.01.006
- Mei, M., Ni, J., Liu, D., Jin, P., & Sun, L. (2013). EUS elastography for diagnosis of solid pancreatic masses: a meta-analysis. *Gastrointestinal Endoscopy*, 77(4), 578–89. doi:10.1016/j.gie.2012.09.035
- Miyamoto, H., Miura, T., Isayama, H., Masuzaki, R., Koike, K., & Ohe, T. (2011). Stiffness of the first annular pulley in normal and trigger fingers. *The Journal of Hand Surgery*, 36(9), 1486–91. doi:10.1016/j.jhssa.2011.05.038
- Miyamoto, N., Hirata, K., Kanehisa, H., & Yoshitake, Y. (2015). Validity of measurement of shear modulus by ultrasound shear wave elastography in human pennate muscle. *PloS One*, 10(4), e0124311. doi:10.1371/journal.pone.0124311
- Moon, W. K., Choi, J. W., Cho, N., Park, S. H., Chang, J. M., Jang, M., & Kim, K. G. (2010). Computer-aided analysis of ultrasound elasticity images for classification of benign and malignant breast masses. *AJR. American Journal of Roentgenology*, 195(6), 1460–5. doi:10.2214/AJR.09.3140
- Moseley, A. M., & Adams, R. (1991). Measurement of passive ankle dorsiflexion: Procedure and reliability. *Australian Journal of Physiotherapy*, 37(3), 175–181.
- Mueller-Wohlfahrt, H.-W., Haensel, L., Mithoefer, K., Ekstrand, J., English, B., McNally, S., ... Uebliacker, P. (2013). Terminology and classification of muscle injuries in sport: the Munich consensus statement. *British Journal of Sports Medicine*, 47(6), 342–50. doi:10.1136/bjsports-2012-091448
- Muthupillai, R., Lomas, D. J., Rossman, P. J., Greenleaf, J. F., Manduca, A., & Ehman, R. L. (1995). Magnetic resonance elastography by direct visualization of propagating acoustic strain waves. *Science*, 269(5232), 1854–7.
- Neely, F. G. (1998). Biomechanical risk factors for exercise-related lower limb injuries. *Sports Medicine*, 26(6), 395–413. doi:10.2165/00007256-199826060-00003

- Nightingale, K., Soo, M. S., Nightingale, R., & Trahey, G. (2002). Acoustic radiation force impulse imaging: in vivo demonstration of clinical feasibility. *Ultrasound in Medicine & Biology*, 28(2), 227–235. doi:10.1016/S0301-5629(01)00499-9
- Nightingale, K., Stutz, R., & Trahey, G. (2002). Acoustic Radiation Force Impulse Imaging of In Vivo Vastus Medialis Muscle. *Ultrasonic Imaging*, 24(2), 100–8. doi:10.1177/016173460202400203
- Niitsu, M., Michizaki, A., Endo, A., Takei, H., & Yanagisawa, O. (2011). Muscle hardness measurement by using ultrasound elastography: a feasibility study. *Acta Radiologica (Stockholm, Sweden : 1987)*, 52(1), 99–105. doi:10.1258/ar.2010.100190
- Nordez, A., Gennisson, J. L., Casari, P., Catheline, S., & Cornu, C. (2008). Characterization of muscle belly elastic properties during passive stretching using transient elastography. *Journal of Biomechanics*, 41(10), 2305–11. doi:10.1016/j.jbiomech.2008.03.033
- O'Brien A., J., Edwards E., H., Finlayson J., K., & Kerr, G. (2012). Understanding the relationships between the calf muscle pump, ankle range of motion and healing for adults with venous leg ulcers: a review of the literature. *Wound Practice & Research*, 20(2), 80–85.
- O'Brien, M. (2005). The Anatomy of the Achilles Tendon. *Foot and Ankle Clinics*, 10(2), 225–238. doi:10.1016/j.fcl.2005.01.011
- Oida, T., Amano, a, & Matsuda, T. (2004). Magnetic resonance elastography: in vivo measurements of elasticity for human tissue. *International Conference Informatics Research for Development of Knowledge Society Infrastructure*, 57–64. doi:10.1109/ICKS.2004.1313409
- Ooi, C. C., Malliaras, P., Schneider, M. E., & Connell, D. A. (2014). “Soft, hard, or just right?” Applications and limitations of axial-strain sonoelastography and shear-wave elastography in the assessment of tendon injuries. *Skeletal Radiol*, 43(1), 1–12. doi:10.1007/s00256-013-1695-3
- Opačić, D. (2015). Endoscopic ultrasound elastography strain histograms in the evaluation of patients with pancreatic masses. *World Journal of Gastroenterology*, 21(13), 4014. doi:10.3748/wjg.v21.i13.4014
- Ophir, J., Céspedes, I., Ponnekanti, H., Yazdi, Y., & Li, X. (1991). Elastography: a quantitative method for imaging the elasticity of biological tissues. *Ultrasonic Imaging*, 13(2), 111–34.
- Orlacchio, A., Bolacchi, F., Antonicoli, M., Coco, I., Costanzo, E., Tosti, D., ... Simonetti, G. (2012). Liver elasticity in NASH patients evaluated with real-time elastography (RTE). *Ultrasound in Medicine & Biology*, 38(4), 537–44. doi:10.1016/j.ultrasmedbio.2011.12.023
- Paparo, F., Corradi, F., Cevasco, L., Revelli, M., Marziano, A., Molini, L., ... Rollandi, G. A. (2014). Real-time elastography in the assessment of liver fibrosis: a review of qualitative and semi-quantitative methods for elastogram analysis. *Ultrasound in Medicine & Biology*, 40(9), 1923–33. doi:10.1016/j.ultrasmedbio.2014.03.021
- Park, S. H., Kim, S. J., Kim, E.-K., Kim, M. J., Son, E. J., & Kwak, J. Y. (2009). Interobserver agreement in assessing the sonographic and elastographic features of malignant thyroid nodules. *AJR. American Journal of Roentgenology*, 193(5), W416–23. doi:10.2214/AJR.09.2541

- Pavan, P. G., Stecco, A., Stern, R., & Stecco, C. (2014). Painful connections: densification versus fibrosis of fascia. *Current Pain and Headache Reports*, 18(8), 441. doi:10.1007/s11916-014-0441-4
- Potter, C. L., Cairns, M. C., & Stokes, M. (2012). Use of ultrasound imaging by physiotherapists: A pilot study to survey use, skills and training. *Manual Therapy*, 17(1), 39–46. doi:10.1016/j.math.2011.08.005
- Prateepavanich, P., Kupniratsaikul, V., & Charoensak, T. (1999). The relationship between myofascial trigger points of gastrocnemius muscle and nocturnal calf cramps. *Journal of the Medical Association of Thailand*, 82(5), 451–9.
- Ringleb, S. I., Bensamoun, S. F., Chen, Q., Manduca, A., An, K. N., & Ehman, R. L. (2007). Applications of magnetic resonance elastography to healthy and pathologic skeletal muscle. *Journal of Magnetic Resonance Imaging*, 25(2), 301–309. doi:10.1002/jmri.20817
- Rios-Diaz, J., Martinez-Paya, J., del Baño-Aledo, M. E., de Groot-Ferrando, A., Paloma, B.-C., & David, F.-R. (2015). Sonoelastography of the plantar fascia; reproducibility and pattern description in healthy subjects and symptomatic subjects.
- Roskopt, A. B., Ehrmann, C., Buck, F. M., Gerber, C., & Flück, M. (2016). Quantitative Shear-Wave US Elastography of the Supraspinatus Muscle : Reliability of the Method and Relation to Tendon Integrity and Muscle Quality 1. *Radiology*, 278(2), 465– 474. doi:10.1148/radiol.2015150908
- Săftoiu, A., Vilmann, P., Gorunescu, F., Gheonea, D. I., Gorunescu, M., Ciurea, T., ... Iordache, S. (2008). Neural network analysis of dynamic sequences of EUS elastography used for the differential diagnosis of chronic pancreatitis and pancreatic cancer. *Gastrointestinal Endoscopy*, 68(6), 1086–1094. doi:10.1016/j.gie.2008.04.031
- Săftoiu, A., Vilmann, P., Gorunescu, F., Janssen, J., Hocke, M., Larsen, M., ... Ciurea, T. (2011). Accuracy of endoscopic ultrasound elastography used for differential diagnosis of focal pancreatic masses: a multicenter study. *Endoscopy*, 43(7), 596–603. doi:10.1055/s-0030-1256314
- Saftoui, A., Gheonea, D. I., & Ciurea, T. (2007). Hue histogram analysis of real-time elastography images for noninvasive assessment of liver fibrosis. *AJR Am.J Roentgenol.*, 189(1546-3141 (Electronic)), W232–W233. doi:10.2214/AJR.07.2571
- Sahrmann, S. (2002). *Diagnosis and Treatment of Movement Impairment Syndromes*. Philadelphia, U.S.A. (First Ed.). Mosby.
- Sammut, E., & Searle-Barnes, P. (1998). *Osteopathic Diagnosis*. Cheltenham, UK: Stanley Thornes.
- Sandrin, L., Fourquet, B., Hasquenoph, J.-M., Yon, S., Fournier, C., Mal, F., ... Palau, R. (2003). Transient elastography: a new noninvasive method for assessment of hepatic fibrosis. *Ultrasound in Medicine & Biology*, 29(12), 1705–1713. doi:10.1016/j.ultras medbio.2003.07.001
- Sarvazyan, A., J. Hall, T., W. Urban, M., Fatemi, M., R. Aglyamov, S., & S. Garra, B. (2011). An Overview of Elastography-An Emerging Branch of Medical Imaging. *Current Medical Imaging Reviews*, 7(4), 255–282. doi:10.2174/157340511798038684

- Schleip, R., Naylor, I. L., Ursu, D., Melzer, W., Zorn, A., Wilke, H. J., ... Klingler, W. (2006). Passive muscle stiffness may be influenced by active contractility of intramuscular connective tissue. *Medical Hypotheses*, 66(1), 66–71. doi:10.1016/j.mehy.2005.08.025
- Schneider, C. A., Rasband, W. S., & Eliceiri, K. W. (2012). NIH Image to ImageJ: 25 years of image analysis. *Nature Methods*, 9(7), 671–5.
- Sconfienza, L. M., Silvestri, E., & Cimmino, M. A. (2010). Achilles tendon sonoelastography in the evaluation of painful in amateur athletes. *Clinical and Experimental Rheumatology*, 28(3), 373–378.
- Sikdar, S., Shah, J. P., Gilliams, E., Gebreab, T., & Gerber, L. H. (2008). Assessment of myofascial trigger points (MTrPs): a new application of ultrasound imaging and vibration sonoelastography. *Conference Proceedings : ... Annual International Conference of the IEEE Engineering in Medicine and Biology Society. IEEE Engineering in Medicine and Biology Society. Annual Conference, 2008*, 5585–8. doi:10.1109/IEMBS.2008.4650480
- Simons, G. D., & Mense, S. (1998). Understanding and measurement of muscle tone as related to clinical muscle pain. *Pain*, 75(1), 1–17. doi:10.1016/S0304-3959(97)00102-4
- Sinkus, R., Tanter, M., Catheline, S., Lorenzen, J., Kuhl, C., Sondermann, E., & Fink, M. (2005). Imaging anisotropic and viscous properties of breast tissue by magnetic resonance-elastography. *Magnetic Resonance in Medicine*, 53(2), 372–387. doi:10.1002/mrm.20355
- Solberg, G., Gur, V., & Adar, E. (2007). *Postural disorders and musculoskeletal dysfunction: diagnosis, prevention and treatment*. Elsevier Health Sciences.
- Sporea, I., Bota, S., Jurchis, A., Sirli, R., Grădinaru-Tascău, O., Popescu, A., ... Szilaski, M. (2013). Acoustic Radiation Force Impulse and Supersonic Shear Imaging Versus Transient Elastography for Liver Fibrosis Assessment. *Ultrasound in Medicine & Biology*, 39(11), 1933–1941. doi:10.1016/j.ultras medbio.2013.05.003
- Stecco, A., Gesi, M., Stecco, C., & Stern, R. (2013). Fascial Components of the Myofascial Pain Syndrome. *Current Pain and Headache Reports*, 17(8), 1–10. doi:10.1007/s11916-013-0352-9
- Stecco, A., Meneghini, A., Stern, R., Stecco, C., & Imamura, M. (2013). Ultrasonography in myofascial neck pain: randomized clinical trial for diagnosis and follow-up. *Surgical and Radiologic Anatomy*. doi:10.1007/s00276-013-1185-2
- Stecco, C., Pavan, P. G., Porzionato, A., Macchi, V., Lancerotto, L., Carniel, E. L., ... De Caro, R. (2009). Mechanics of crural fascia: from anatomy to constitutive modelling. *Surgical And Radiologic Anatomy: SRA*, 31(7), 523–529. doi:10.1007/s00276-009-0474-2
- Stecco, C., Pavan, P., Pachera, P., De Caro, R., & Natali, A. N. (2014). Investigation of the mechanical properties of the human crural fascia and their possible clinical implications. *Surgical and Radiologic Anatomy*, 36(1), 25–32. doi:10.1007/s00276-013-1152-y
- Stecco, C., Stern, R., Porzionato, A., Macchi, V., Masiero, S., Stecco, A., & De Caro, R. (2011). Hyaluronan within fascia in the etiology of myofascial pain. *Surgical and Radiologic Anatomy*, 33(10), 891–896. doi:10.1007/s00276-011-0876-9

- Stecco, L. (2012). *Fascial manipulation for musculoskeletal pain*. PICCIN.
- Syversveen, T., Midtvedt, K., Berstad, A. E., Brabrand, K., Strøm, E. H., & Abildgaard, A. (2012). Tissue elasticity estimated by acoustic radiation force impulse quantification depends on the applied transducer force: an experimental study in kidney transplant patients. *European Radiology*, 22(10), 2130–7. doi:10.1007/s00330-012-2476-4
- Tabrizi, P., McIntyre, W. M., Quesnel, M. B., & Howard, A. W. (2000). Limited dorsiflexion predisposes to injuries of the ankle in children. *The Journal Of Bone And Joint Surgery. British Volume*, 82(8), 1103–1106. doi:10.1302/0301-620X.82B8.10134
- Talwalkar, J. A., Kurtz, D. M., Schoenleber, S. J., West, C. P., & Montori, V. M. (2007). Ultrasound-based transient elastography for the detection of hepatic fibrosis: systematic review and meta-analysis. *Clinical Gastroenterology and Hepatology*, 5(10), 1214–20. doi:10.1016/j.cgh.2007.07.020
- Tan, S., Kudas, S., Ozcan, A. S., Ipek, A., Karaoglanoglu, M., Arslan, H., & Bozkurt, M. (2012). Real-time sonoelastography of the Achilles tendon: pattern description in healthy subjects and patients with surgically repaired complete ruptures. *Skeletal Radiology*, 41(9), 1067–1072. doi:10.1007/s00256-011-1339-4
- Terada, M., Pietrosimone, B. G., & Gribble, P. A. Therapeutic interventions for increasing ankle dorsiflexion after ankle sprain: a systematic review. *Journal of Athletic Training*, 48(5), 696–709. doi:10.4085/1062-6050-48.4.11
- Teyhen, D., & Koppenhaver, S. (2011). Rehabilitative ultrasound imaging. *Journal of Physiotherapy*, 57(3), 196. doi:10.1016/S1836-9553(11)70044-3
- Teyhen, D. S., Miltenberger, C. E., Deiters, H. M., Toro, Y. M. Del, Pulliam, J. N., Childs, J. D., ... Flynn, T. W. (2005). Abdominal Drawing-in Maneuver in. *Journal of Orthopaedic & Sports Physical Therapy*, 35(6), 346–355.
- Thompson, J. A., O'Sullivan, P. B., Briffa, N. K., & Neumann, P. (2006). Assessment of voluntary pelvic floor muscle contraction in continent and incontinent women using transperineal ultrasound, manual muscle testing and vaginal squeeze pressure measurements. *International Urogynecology Journal and Pelvic Floor Dysfunction*, 17(6), 624–630. doi:10.1007/s00192-006-0081-2
- Tsochatzis, E. A., Gurusamy, K. S., Ntaoula, S., Cholongitas, E., Davidson, B. R., & Burroughs, A. K. (2011). Elastography for the diagnosis of severity of fibrosis in chronic liver disease: a meta-analysis of diagnostic accuracy. *Journal of Hepatology*, 54(4), 650–9. doi:10.1016/j.jhep.2010.07.033
- Tucker, K., Hodges, P. W., Van Den Hoorn, W., Nordez, A., & Hug, F. (2014). Does stress within a muscle change in response to an acute noxious stimulus? *PLoS ONE*, 9(3), e91899. doi:10.1371/journal.pone.0091899
- Turo, D., Otto, P., Hossain, M., Gebreab, T., Armstrong, K., Rosenberger, W. F., ... Sikdar, S. (2015). Novel Use of Ultrasound Elastography to Quantify Muscle Tissue Changes After Dry Needling of Myofascial Trigger Points in Patients With Chronic Myofascial Pain. *Journal of Ultrasound in Medicine*, 34(12), 2149–61. doi:10.7863/ultra.14.08033

- Van Gent, R. N., Siem, D., van Middelkoop, M., van Os, A. G., Bierma-Zeinstra, S. M. A., Koes, B. W., & Taunton, J. E. (2007). Incidence and determinants of lower extremity running injuries in long distance runners: a systematic review \* COMMENTARY. *British Journal of Sports Medicine*, *41*(8), 469–480. doi:10.1136/bjsm.2006.033548
- Venkatesh, S. K., Yin, M., & Ehman, R. L. (2013). Magnetic resonance elastography of liver: technique, analysis, and clinical applications. *Journal of Magnetic Resonance Imaging : JMRI*, *37*(3), 544–55. doi:10.1002/jmri.23731
- Wang, C.-Z., Li, T.-J., & Zheng, Y.-P. (2014). Shear modulus estimation on vastus intermedius of elderly and young females over the entire range of isometric contraction. *PloS One*, *9*(7), e101769. doi:10.1371/journal.pone.0101769
- Wang, H., Brylka, D., Sun, L. N., Lin, Y. Q., Sui, G. Q., & Gao, J. (2013). Comparison of strain ratio with elastography score system in differentiating malignant from benign thyroid nodules. *Clinical Imaging*, *37*(1), 50–55. doi:10.1016/j.clinimag.2012.04.003
- Wang, S. S., Whitney, S. L., Burdett, R. G., & Janosky, J. E. (1993). Lower extremity muscular flexibility in long distance runners. *The Journal of Orthopaedic and Sports Physical Therapy*, *17*(2), 102–107. doi:10.2519/jospt.1993.17.2.102
- Wanner, M., Probst-Hensch, N., Kriemler, S., Meier, F., Bauman, A., & Martin, B. W. (2013). What physical activity surveillance needs: validity of a single-item questionnaire. *British Journal of Sports Medicine*. doi:10.1136/bjsports-2012-092122
- Ward, R. C. (2002). *Foundations for Osteopathic Medicine* (2nd ed.). Philadelphia: Lippincott Williams & Wilkins.
- Weerapong, P., Hume, P. A., & Kolt, G. S. (2005). The mechanisms of massage and effects on performance, muscle recovery and injury prevention. *Sports Medicine*, *35*(3), 235–56.
- Witvrouw, E., Lieven, D., Peter, A., D'Have, T., & Cambier, D. (2003). Muscle Flexibility as a risk factor for developing muscle injuries in male professional soccer players. *The American Journal of Sports Medicine*, *31*(1).
- Xu, G., Feng, L., Yao, M., Wu, J., Guo, L., Yao, X., ... Xu, H. (2014). Original Article A new 5-grading score in the diagnosis of prostate cancer with real-time elastography, *7*(7), 4128–4135.
- Xu, W., Shi, J., Zeng, X., Li, X., Xie, W.-F., Guo, J., & Lin, Y. (2011). EUS elastography for the differentiation of benign and malignant lymph nodes: a meta-analysis. *Gastrointestinal Endoscopy*, *74*(5), 1001–9; quiz 1115.e1–4. doi:10.1016/j.gie.2011.07.026
- Xydeas, T., Siegmann, K., Sinkus, R., Krainick-Strobel, U., Miller, S., & Claussen, C. D. (2005). Magnetic Resonance Elastography of the Breast. *Investigative Radiology*, *40*(7), 412–420. doi:10.1097/01.rli.0000166940.72971.4a
- Yavuz, A., Bora, A., Bulut, M. D., Batur, A., Milanlioglu, A., Göya, C., & Andic, C. (2015). Acoustic Radiation Force Impulse (ARFI) elastography quantification of muscle stiffness over a course of gradual isometric

contractions: A preliminary study. *Medical Ultrasonography*, 17(1), 49–57.  
doi:10.11152/mu.2013.2066.171.yvz

- Yin, M., Talwalkar, J. A., Glaser, K. J., Manduca, A., Grimm, R. C., Rossman, P. J., ... Ehman, R. L. (2007). Assessment of hepatic fibrosis with magnetic resonance elastography. *Clinical Gastroenterology and Hepatology*, 5(10), 1207–1213.e2. doi:10.1016/j.cgh.2007.06.012
- Ying, L., Hou, Y., Zheng, H.-M., Lin, X., Xie, Z.-L., & Hu, Y.-P. (2012). Real-time elastography for the differentiation of benign and malignant superficial lymph nodes: a meta-analysis. *European Journal of Radiology*, 81(10), 2576–84. doi:10.1016/j.ejrad.2011.10.026
- Yoshitake, Y., Takai, Y., Kanehisa, H., & Shinohara, M. (2014). Muscle shear modulus measured with ultrasound shear-wave elastography across a wide range of contraction intensity. *Muscle & Nerve*, 50(1), 103–113. doi:10.1002/mus.24104
- You, J.-Y., Lee, H.-M., Luo, H.-J., Leu, C.-C., Cheng, P.-G., & Wu, S.-K. (2009). Gastrocnemius tightness on joint angle and work of lower extremity during gait. *Clinical Biomechanics*, 24(9), 744–750. doi:10.1016/j.clinbiomech.2009.07.002
- Zhang, B., Ma, X., Zhan, W., Zhu, F., Li, M., Huang, J., ... Wei, Y. (2014). Real-time elastography in the diagnosis of patients suspected of having prostate cancer: a meta-analysis. *Ultrasound in Medicine & Biology*, 40(7), 1400–7. doi:10.1016/j.ultrasmedbio.2014.02.020
- Zhi, H., Xiao, X.-Y., Yang, H.-Y., Ou, B., Wen, Y.-L., & Luo, B.-M. (2010). Ultrasonic elastography in breast cancer diagnosis: strain ratio vs 5-point scale. *Academic Radiology*, 17(10), 1227–33. doi:10.1016/j.acra.2010.05.004
- Zhu, Q.-L., Jiang, Y.-X., Liu, J.-B., Liu, H., Sun, Q., Dai, Q., & Chen, X. (2008). Real-time ultrasound elastography: its potential role in assessment of breast lesions. *Ultrasound in Medicine & Biology*, 34(8), 1232–8. doi:10.1016/j.ultrasmedbio.2008.01.004

## SECTION II – Manuscript

Note: This manuscript is formatted according to the Guidelines for Authors for the *Journal of Bodywork and Movement Therapies* available here: <http://goo.gl/ug77p4>



## ABSTRACT

### **Reliability of ultrasound imaging measures of soft tissues stiffness using elastography in the posterior aspect of the leg**

**Objectives:** To evaluate the *intra*-operator and *inter*-operator reliability of ultrasound elastography (UES) imaging in obtaining stiffness measurements of subcutaneous tissue, lateral gastrocnemius, and soleus muscles at rest.

**Design:** Single-group, repeated-measures, reliability study.

**Participants:** A convenience sample of 12 healthy adults (n=3 males, n=9 females, mean  $\pm$  SD age =  $28.9 \pm 5.8$  yrs, height =  $169.6 \pm 9.17$  cm, weight =  $69.6 \pm 13.35$  kg. Physical activity = 9 of the 12 failed to meet the definition of being ‘sufficiently active’) were enrolled in the study and examined in a single session by three operators: two novice UES operators with minimal previous experience, and an experienced operator with > 20 years of experience in musculoskeletal sonography.

**Methods:** UES imaging (acoustic radiation force impulse) was used to acquire elastograms of the subcutaneous tissue, lateral gastrocnemius and soleus muscle with participants lying prone with the ankle in neutral. Three examiners acquired images from all participants during a single session.

**Main Outcome Measures:** Mean colour-hue histograms were generated as a proxy measure of stiffness for the subcutaneous tissue, lateral gastrocnemius, and soleus muscle. Intraclass correlation coefficients (ICC, model 2, 1) and coefficients of variation (CV) were used to estimate reliability. Standard error of measurement and minimal detectable change were calculated to aid interpretation.

**Results:** Point estimates for *intra*-operator reliability were ‘high’ to ‘very high’ (ICC ranging from 0.59 to 0.85 across all tissues). All three operators demonstrated similar levels of *intra*-operator reliability. *Inter*-operator reliability estimates ranged between ‘trivial’ and ‘very high’ (ICC range: -0.07 to 0.87 across all tissues). The *inter*-operator values for subcutaneous tissue had the lowest test-retest reliability in comparison to gastrocnemius and soleus muscle.

**Conclusions:** Operators in this study demonstrated acceptable *intra*-operator reliability of UES measures, for stiffness of the subcutaneous tissue, lateral gastrocnemius and soleus muscle in healthy participants, however, *inter*-operator reliability ranged widely. Therefore, we suggest that UES (acoustic radiation force impulse) can be useful for clinical assessment

when applied by both novice or/and experienced operators, when following our specific protocol. These findings indicate this technique could be potentially useful as a non-invasive measure of muscle stiffness in clinical and research settings.

*Key Words:* leg muscle; gastrocnemius; soleus; reliability; ultrasound elastography

## INTRODUCTION

The muscles of the posterior lower leg are frequently injured in both athletes and non-athletes (Campbell, 2009; Counsel & Breidahl, 2010). The most prevalent injuries include calf tears (Jan Ekstrand et al., 2011) and strains (Mueller-Wohlfahrt et al., 2013). The non-normal viscoelastic properties of the gastrocnemius and soleus muscles are known to be an intrinsic predisposing factor for muscle injury (Cohen, 2009; DiGiovanni, Kuo, Tejwani, Price, Hansen, et al., 2002; McKay et al., 2001), and play an aetiological role in other conditions including cramps (Butler et al., 2002), hypertrophy (Emery, 2002), and myofascial trigger points (Prateepavanich et al., 1999). Amongst some clinical practitioners, there is a view that changes in skeletal muscle stiffness may be improved following therapeutic approaches such as dry needling (Turo et al., 2015), myofascial release (Luomala et al., 2014), static stretching (Akagi & Takahashi, 2013), and massage (Crommert et al., 2015).

Traditionally, the assessment of altered tissue texture has been performed clinically using manual palpation (Li & Snedeker, 2011). Ultrasound elastography (UES) is a widely available imaging technique that can quantify soft tissue stiffness (Klauser et al., 2010). While initial clinical applications of this technology have been largely in detecting soft tissue tumours (Krouskop, Wheeler, Kallel, Garra, & Hall, 1998; B. Liu et al., 2015) and in the diagnosis of liver pathology (Bota et al., 2013; Fraquelli et al., 2007), UES has recently gained popularity in the musculoskeletal field (De Zordo et al., 2010; Drakonaki et al., 2012; Klauser et al., 2010). Ultrasound elastography is a non-invasive, simple to use and portable technique (Drakonaki & Allen, 2010; Gennisson, Deffieux, Fink, & Tanter, 2013). Of the UES methods available, Acoustic Radiation Force Impulse (ARFI) offers the advantage of less tissue distortion than shear-wave and strain elastography (Nightingale, Soo, et al., 2002), as well as improved accessibility to deeper tissues, and is less operator dependant than strain elastography (Bamber et al., 2013). To date, a limited number of studies have assessed skeletal muscle stiffness with ARFI elastography, including normative data of healthy neck muscle stiffness (Kuo et al., 2013), muscle stiffness at different levels of voluntary contraction (Nightingale, Stutz, et al., 2002; Yavuz et al., 2015) and stiffness in healthy and non-normal muscle (Badea et al., 2014; Cho & Nam, 2015). Only Cho & Nam (2015) examined lower limb muscles with ARFI, and performed this in patients with spinal cord

injury. Despite the promising clinical utility of this technique, the reliability of AFRI elastography in assessing skeletal muscle stiffness is yet not well understood. Recently, the application of ultrasound imaging has expanded into musculoskeletal practitioners, especially amongst physiotherapists (McKiernan et al., 2013) who are applying ultrasound to improve rehabilitation outcomes for patients with low back pain (Ferreira, Ferreira, & Hodges, 2004; D. S. Teyhen et al., 2005), dysfunction in the scapular muscles (Bentman, O'Sullivan, & Stokes, 2010) and bladder incontinence (Thompson, O'Sullivan, Briffa, & Neumann, 2006). However, not all practitioners using rehabilitative ultrasound are formally trained in the use of ultrasound imaging (Potter et al., 2012), hence it is likely there are a large number of novice operators using ultrasound in clinical practice. The application of AFRI elastography by novice operators to assess lower leg muscle stiffness as part of rehabilitation and injury prevention is one potential application, however, little is known about the reliability of novice operators for these measures. Therefore, the aim of this study was to investigate the *intra*-operator and *inter*-operator reliability of both novice and experienced operator in the use of UES at assessing the stiffness of the subcutaneous tissues, lateral gastrocnemius and soleus muscle.

## METHOD

### Design

This single-group repeated-measures study to investigating *inter-* and *intra-* operator reliability of novice and experienced examiners to measure colour hue from elastography imaging of the posterior calf muscles which involved a test- retest assessment within a single session.

The methodology of this study was designed following the quality appraisal of reliability studies (QAREL) (N. P. Lucas et al., 2010).

### Participants

A convenience sample of twelve volunteers, were recruited using posters placed in different areas of the Unitec campus and word-of-mouth. Inclusion criteria were: (1) male or females; (2) aged 18 to 60 years. Exclusion criteria were: (1) previous diagnosis of any neurological condition affecting the lower leg (i.e. spasticity or contractures); (2) systemic disorder that could have an effect on the muscles of the area; (3) recent surgeries or trauma (i.e. muscle tear) of the leg; (4) any disorder that could potentially be aggravated by the study (i.e. peripheral neuropathy, diabetes, ulcer, skin allergy to the gel). All participants provided informed consent in writing, the rights of the participants were protected, and the study was approved by the Unitec Research Ethics Committee (UREC 2015- 1003). Participants were asked to avoid any treatment, exercise or any exercise related activity (running, etc.) on the day of testing.

The inclusion criteria for this study was intended to be broad to ensure that the sample is representative of the population that can be utilized in future research, and clinical practice.

### Examiners

Three examiners were involved in the study. Two Master students of Osteopathy were the novice examiners and an experienced sonographer. Neither of the novice examiners had previously used ultrasound elastography in their clinical practice. Therefore, a 6.5 hour

hands-on practical course in ultrasound and 13 hours of piloting with the experienced sonographer for familiarizing with the specific protocol of the study were undertaken. The experienced sonographer specialized in musculoskeletal sonography with over 20 years of experience in the field. Examiners were selected to match those who would typically perform the rehabilitative ultrasound elastography in the clinical setting.

## Procedures

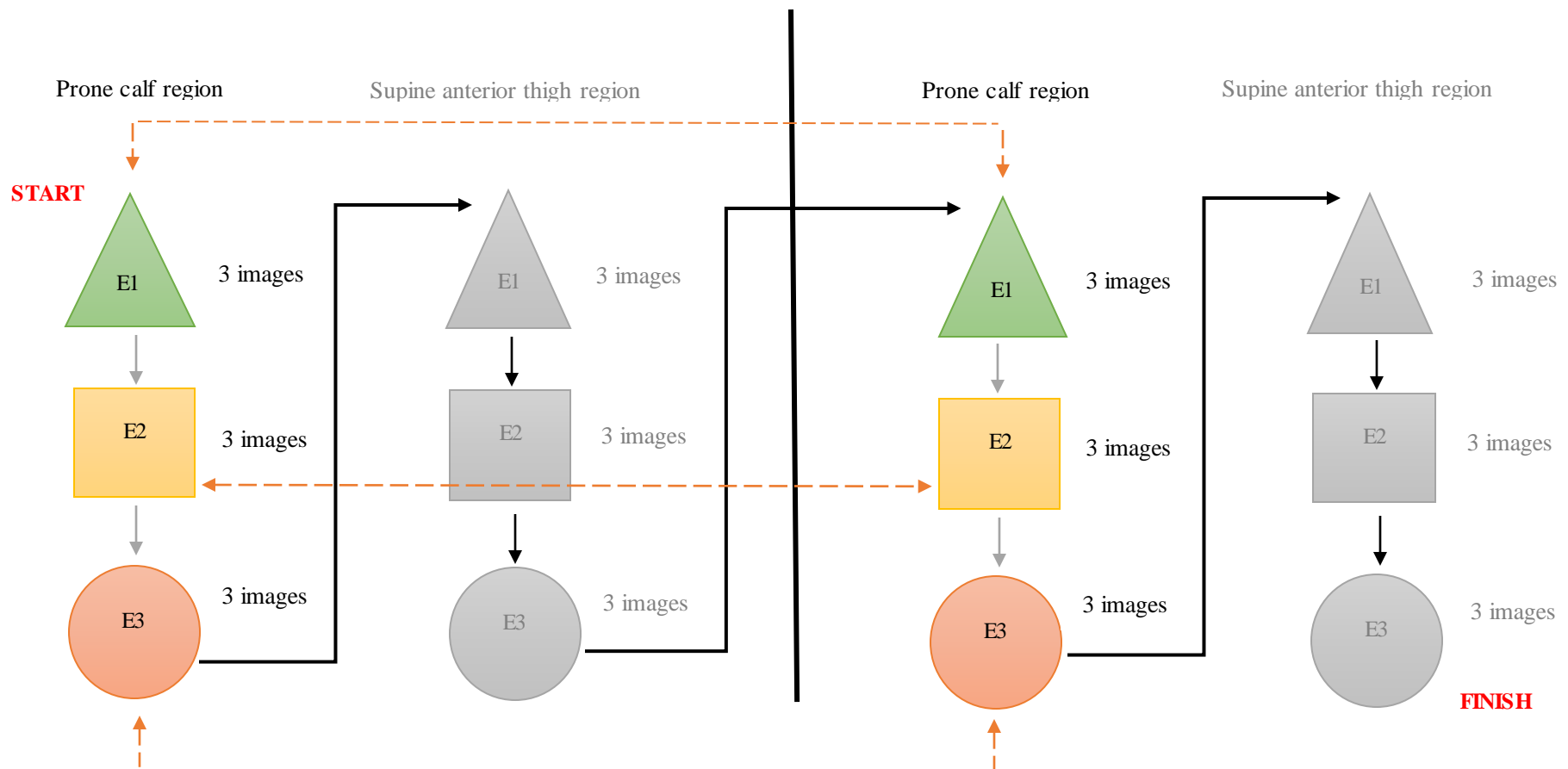
After providing consent, each participant was allocated a unique number to enable files to be saved appropriately. Ultrasound elastography images of the lateral gastrocnemius, soleus and subcutaneous tissue of the non-dominant leg were captured. A 2013 Phillips iU22 ultrasound scanner (Philips Medical Systems; WA, USA) was used, with manufacturer installed acoustic radiation force impulse software. A 50mm linear array transducer of 12-7 MHz was used. Depth and focus was adjusted for a clear visualisation of the tissues of the region of interest. A manufacturer pre-set mode (breast) with semi-transparent overlay of the elastogram onto the B-mode echogram was employed to assist judgement of the anatomical location of the ultrasound and elastographic imaging.

The layout of image acquisition is illustrated in figure 1. Image acquisition for each participant was performed 3 times by each of the three examiners in a first set. This procedure was performed twice in the session. A five minute interval was allowed between the first and second set of image collection, allowing participants to stand- up, rest and reposition for the second set of imaging acquisition to take place. The second set of measurements provided the data on *intra*-operator reliability. *Inter*-operator reliability was calculated by comparing each examiner with the others. Within the same session, images of the anterior thigh were captured as part of another study (Sharma, 2016). This designed allowed for convenience of utilizing the same examiners, subjects, and elastography ultrasound equipment. Participants were asked to not be involved in any physical activity on the day previous of the research.

Imaging of the lateral gastrocnemius, soleus and subcutaneous tissue were performed with participants lying prone, with the ankle positioned off the edge of the table in a neutral position and the angle of knee flexion will be controlled (Cho et al., 2014). Non- dominant

leg was scanned for this research. Foot dominance was determined by asking participants which leg they used to kick a ball (Gabbard & Hart, 1996). Each examiner applied sufficient gel on the posterior aspect of the leg to ensure adequate image quality and with each image examiners were in charge of re-identifying the region of interest. No skin markings were employed to find the region of interest. Measures were performed by applying minimal scanning pressure in order to reduce the variations due to pressure changes (Kot, Zhang, Lee, Leung, & Fu, 2012). After acquiring the three images, the examiner cleaned the gel from the leg, so that the participant was ready for the next examiner to proceed.

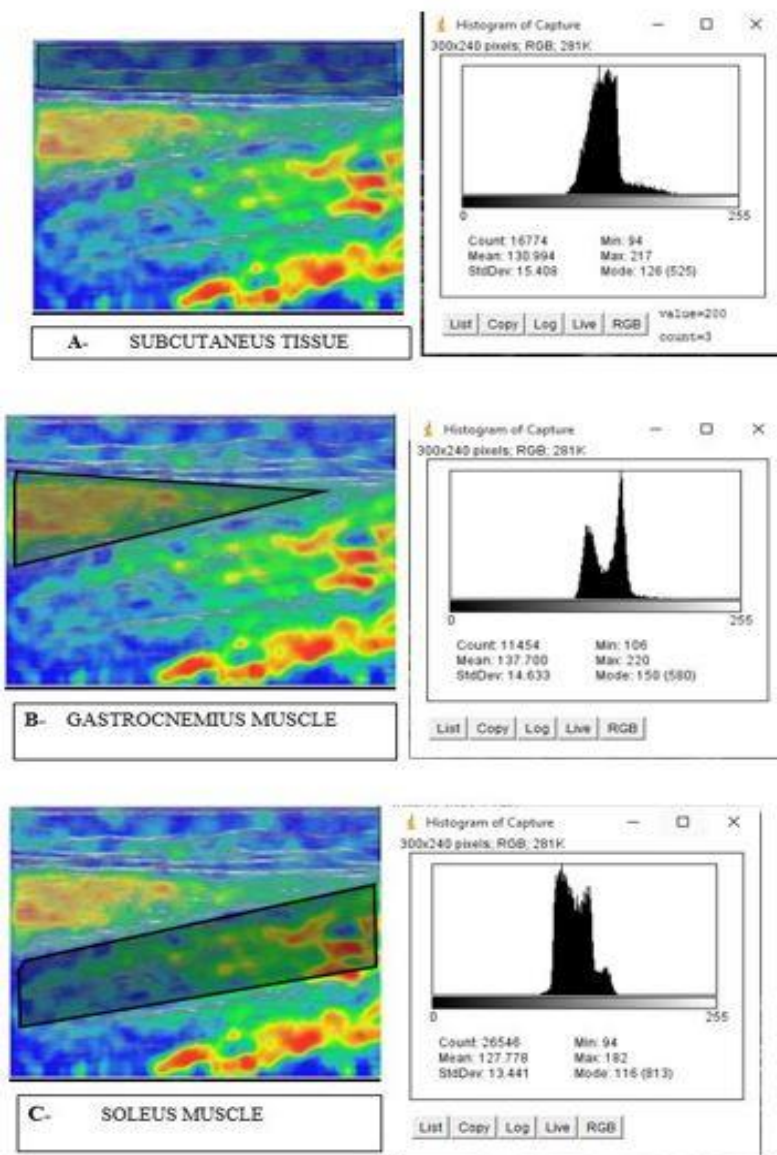
The region of interest was identified by placing the transducer in cross-section over the lower insertion of the Achilles tendon then moving superiorly until the lateral head of the gastrocnemius was visualized at the muscular tendon junction. Once over the lateral gastrocnemius, the transducer was then rotated longitudinally to the long axis of the leg and the image was captured. This region correlates with a fascial manipulation point described by (Luomala et al., 2014; L. Stecco, 2012). All examiners followed the same methodological protocol, and were blinded to each other's measurements and blinded to their own prior measurements. Examiners were also blinded to any additional clinical information from the participants.



**Figure 1.** Above is the layout of the sequence of the data collection routine. The triangle represents the 1<sup>st</sup> examiner (E1); the square represents the 2<sup>nd</sup> examiner (E2) and the circle represents the 3<sup>rd</sup> examiner (E3). The greyed areas represent the scanning of the thigh region for a study conducted parallel to the current study (Sharma, 2016). The coloured shapes represent the scanning for the current study. The routine began with the 1<sup>st</sup> examiner scanning the ROI in the calf with the participant in prone position; followed by the 2<sup>nd</sup> and 3<sup>rd</sup> examiners; the participant then asked to stand and lay supine (this marked the end of set 1). The 1<sup>st</sup> examiner scans the ROI in the anterior thigh; followed by the 2<sup>nd</sup> and 3<sup>rd</sup> examiners. The whole process is repeated again (set 2) for data collection for the *intra*-operator reliability. The *intra*-operator reliability is shown above via the dotted orange lines for each examiner

## Extraction and processing of images

All images were saved for offline analysis. The processing of the images were performed by using ImageJ software on a different date than the images were obtained. ImageJ software allowed the analysis of the hue histogram and calculation of mean pixel values of each elastogram. The different tissues in the region of interest were selected individually from each elastogram and analysed with ImageJ as shown in figure 2 (A, B and C). Mean pixel colour values were calculated for each tissue. The same methodology has been previously described (Săftoiu et al., 2008; Saftoui et al., 2007). To ensure familiarity with extraction procedures the researcher practiced image processing using a sample of images recorded from pilot work. Determining the data extraction challenges is useful, particularly if reliability is low, as it allows partitioning of error into biological and operator sources.



**Figure 2.** Data extraction of ROI. (A) Shaded selection of subcutaneous tissue with respective histogram. (B) Shaded selection of lateral gastrocnemius muscle with respective histogram. (C) Shaded selection of soleus muscle with respective histogram. Copyright © 2016 [COPYRIGHT PAULA TOLEDO].

## Data Analysis

*Intra-* and *inter-*operator reliability will be evaluated using the coefficient of variation (CV) and Intraclass correlation coefficient (ICC) (Chino et al., 2012). The standard error of measurement,  $SEM = \text{pooled } \sigma * \sqrt{1-ICC}$ , and minimal detectable change for a 95% confidence interval (CI),  $MDC = SEM * \sqrt{2} * 1.96$  was calculated to assess the precision of the repeated measures. The CV is the ratio of the standard deviation ( $\sigma$ ) to the mean ( $\mu$ ). The model of ICC used was ICC (2, 1) two-way random single measure. The level of significance will be set at  $p < 0.05$ . Interpretation and qualitative descriptors for reliability coefficients will be based on Hopkins (2000) where 0.0 to 0.1 was 'trivial', 0.1 to 0.3 is 'low', 0.3 to 0.5 was 'moderate', 0.5 to 0.7 was 'high', and 0.7 to 1 'very high or near perfect'.

## RESULTS

Twelve participants (n=9 females, n=3 males) were enrolled in the study. The mean  $\pm$  SD age of participants was  $28.9 \pm 5.8$  years of age, (range 22 – 42 years); the mean height was  $169.6 \pm 9.17$  cm (range 158 – 187cm); and the mean body mass was  $69.6 \pm 13.35$  kg (range 50– 97kg). Nine out of 12 participants failed to meet the definition of being ‘sufficiently active’ (Wanner et al., 2013), which involved participants to achieve 30 min of moderate-to-vigorous activity on at least 5 days/week.

### *Intra-operator reliability*

A summary of the results for *intra-operator* reliability of the subcutaneous, lateral gastrocnemius and soleus muscle stiffness for the three examiners is shown in table 1. The test-retest *intra-operator* reliability coefficients for all tissues, across all operators, was ‘high’ to ‘very high’, ranging from 0.59 where lateral gastrocnemius muscle obtained by novice one, to 0.85 for soleus muscle obtained by novice two. The experienced operator had similar levels of *intra-operator* reliability test-retest reliability compared to both novice operators (‘high’ to ‘very high’). Standard error of measurements are reported in table 1.

### *Inter –operator reliability*

A summary of the results for *inter-operator* reliability of the subcutaneous, lateral gastrocnemius and soleus muscle stiffness for the three examiners is shown in table 3. The test-retest *inter-operator* reliability ranged from ‘trivial’ to ‘very high’ (-0.071 to 0.874). The *inter-operator* values for subcutaneous tissue had the lowest test-retest reliability in comparison to the rest of the tissues, a systematic change was identified in the mean. The mean hue values of the different tissues across all operators are shown in table 4. Coefficient of variation ranged from 1.7% to 5.7% indicating a low level of variability which can be seen in table 2.

**Table 1.** *Intra-* operator reliability of measurements between three examiners

Examiners	Subcutaneous					Gastrocnemius					Soleus				
	ICC	Descriptor*	95%CI	SEM	MDC	ICC	Descriptor*	95%CI	SEM	MDC	ICC	Descriptor*	95%IC	SEM	MDC
Experienced	0.691	'high'	0.224 to 0.900	1.97	5.47	0.783	'very high'	0.406 to 0.932	2.37	6.57	0.745	'very high'	0.326 to 0.919	3.44	9.53
Novice 1	0.657	'high'	0.163 to 0.888	2.24	6.22	0.592	'high'	0.059 to 0.863	3.15	8.72	0.611	'high'	0.087 to 0.870	2.36	6.55
Novice 2	0.708	'high'	0.255 to 0.906	1.42	3.93	0.764	'very high'	0.366 to 0.926	1.96	5.43	0.855	'very high'	0.572 to 0.956	1.34	3.71

\*Note: descriptors were based on suggestions from Hopkins (2000). ICC= Intraclass correlation; CI= confidence interval; SEM= standard error of the measurement; MDC= minimal detectable change.

**Table 2.** Coefficient of variation between investigators according to tissue.

Operators	Coefficient of variation		
	Subcutaneous	Gastrocnemius	Soleus
Experienced	2.8%	3.7%	5.7%
Novice 1	3.6%	3.3%	3.2%
Novice 2	1.7%	2.8%	2.9%

**Table 3.** *Inter-operator reliability*

Operators	Subcutaneous			Gastrocnemius			Soleus		
	ICC	Descriptor*	95% CI	ICC	Descriptor*	95%CI	ICC	Descriptor*	95%CI
<b>Experienced vs Novice 1</b>	-0.071	‘trivial’	-0.600 to 0.502	0.628	‘high’	0.116 to 0.877	0.639	‘high’	0.134 to 0.881
<b>Experienced vs Novice 2</b>	0.501	‘high’	-0.072 to 0.825	0.650	‘high’	0.151 to 0.885	0.455	‘moderate’	-0.131 to 0.805
<b>Novice 1 vs Novice 2</b>	0.220	‘low’	-0.370 to 0.689	0.874	‘very high’	0.621 to 0.962	0.557	‘high’	0.005 to 0.848

\*Note: descriptors were based on suggestions from Hopkins (2000). ICC = intraclass correlation coefficient; CI = confidence interval; SEM = standard error of the measurement; MDC = minimal detectable change.

**Table 4.** Mean hue colour values for tissues

Operators	Subcutaneous				Gastrocnemius				Soleus			
	Min.	Max.	Mean	SD	Min.	Max.	Mean	SD	Min.	Max.	Mean	SD
Experienced	122.4	137.0	131.3	3.7	127.1	145.3	135.6	5.1	105.5	128.6	119.4	6.9
Novice 1	117.4	129.8	125.9	4.6	128.6	144.6	139.1	4.6	118.1	130.6	124.0	4.0
Novice 2	120.3	128.4	123.8	2.1	132.4	147.3	140.7	4.0	116.9	129.9	123.9	3.6

Abbreviations; min.= minimum; max.=maximum, SD= standard deviation;

## DISCUSSION

This study evaluated the *intra*-and *inter*-operator reliability using UES to assess tissue stiffness of subcutaneous tissue, soleus and lateral gastrocnemius muscles in healthy participants within a single session. Colour hue was used as an indirect objective measure of stiffness. To our knowledge there are only five studies that have employed ARFI *in vivo* on muscular structures (Badea et al., 2014; Kuo et al., 2013; Nightingale, Stutz, et al., 2002; Yavuz et al., 2015). However the *intra*-and *inter*-operator reliability of ARFI elastography to assess lower leg muscle stiffness has not been examined before.

Our study demonstrates that operators of different levels of training can use UES to measure stiffness of the subcutaneous tissue, lateral gastrocnemius and soleus muscle at rest with point estimates between 'high' to 'very high' for *intra*-operator reliability (ICC= 0.595- 0.855). In contrast to a wider range for *inter*-operator reliability (-0.071 to 0.874) scoring from 'trivial' to 'very high' reliability (Hopkins, 2000). Consistent with the general pattern in reliability studies, *intra*-operator reliability was generally higher than *inter*-operator reliability (Koppenhaver et al., 2009; Rosskopt et al., 2016). The SEM values were all under 3.44 across all investigated tissues and were associated with low CV values (all below 6%), indicating that there was little variability due to the operator. Although the point estimates were of acceptable reliability they were also associated with wide confidence intervals of poor precision and this is most likely to be attributable to the small sample size rather than due to biological variability. A systematic error was found in the *inter*-operator comparison. The reliability values of this study were better for assessing muscle tissue (for both lateral gastrocnemius and soleus) than for subcutaneous tissue. For muscle tissue, it ranged from 'moderate' to 'very high' while for subcutaneous tissue ranged from 'trivial' to 'high'. These findings suggest that UES may provide an appropriate quantitative measure for documenting change in the stiffness of the gastrocnemius and soleus muscle which is important for the assessment of muscle dysfunction and for determining muscle stiffness changes following treatment.

The results of this study showed that novice operators, when using the protocol within this study, can measure muscular and subcutaneous tissue stiffness with ‘high’ to ‘very high’ reliability. This implies that UES is of acceptable reliability for measuring the stiffness of muscles located in the lower leg.

There are no previous investigations reporting colour hue as a proxy of stiffness for the gastrocnemius and soleus muscle, nor following a similar protocol to the present study, hence there are no direct comparable studies. However other authors such as Chino, Akagi, Dohi, Fukashiro, & Takahashi, (2012); Dorado Cortez et al, (2015); Dubois et al, (2015); Lacourpaille, Hug, Bouillard, Hogrel, & Nordez, (2012) do report values for muscular stiffness for upper and lower limb muscles. Dubois et al. (2015) and Lacourpaille et al. (2015) found *intra*-rater ICC to be ‘near perfect’, with values ranging from 0.87 to 0.95. Lacourpaille et al. (2015) investigated the shear modulus of nine upper and lower limb muscles. Dubois et al. (2015) investigated 11 different muscles and reported a reliability coefficient representing the combination of the lower limb with muscles in a slack and in passive stretch position. These two studies had overall slightly higher *intra*- and *inter*-rater reliability than in the present study. Although, these studies used shear-wave elastography compared to ARFI employed in this study, the accuracy of these two methods is considered to be technically similar (Sporea et al., 2013). Our study was performed under more controlled methodological procedures than these two studies, particularly around description of the representativeness of the sample and raters (item 1 and 2 QAREL) and blinding (item 3, 4, 6 and 7, QAREL) predisposing the chances for bias (N. P. Lucas et al., 2010).

Two study investigated the reliability of UES in obtaining stiffness values on the gastrocnemius muscle (Chino et al., 2012; Dorado Cortez et al., 2015). Chino et al, (2012) investigated the stiffness of this muscle at rest with the ankle in different ranges of plantar and dorsiflexion. While Dorado Cortez et al, (2015) examined the reliability of UES when using the probe in two different planes (transverse and horizontal). Although these two studies had different aims compared to this study, the *intra*-rater findings for the gastrocnemius muscle were similar to those of the present study, reinforcing the strength of our findings.

When comparing the *inter*-rater reliability findings for gastrocnemius muscle, Dorado Cortez et al, (2015) found ‘high’ to ‘very high’ *inter*-rater reliability when assessing the medial gastrocnemius with probe placed parallel to muscle fibres which is a similar approach to that undertaken in this study. Their reliability values compare favourably to those of Dorado Cortez et al, (2015) both ranging between ‘high’ to very high’. This is reassuring as the raters in Dorado Cortez et al, (2015) were experienced radiologist compared to the novice raters in this study.

To our knowledge there is no literature regarding the reliability of UES in obtaining the stiffness of subcutaneous tissue. The results showed that the reliability was ‘high’ for *intra*-operator and ‘trivial’ to ‘high’ for *inter*-operator. This suggests that UES might have potential use for the assessment of sliding interfaces between subcutaneous tissue and underlying muscle, which is essential for appropriate muscle and joint function (Davies, 2014; McCombe, Brown, Slavin, & Morrison, 2001), topic that is of special interest to manual therapists.

Ultrasound imaging is well known to be highly operator dependent (Chiou, Chou, Chiou, Liu, & Chang, 2003) and operator skill can influence reliability (Ellis, Hing, Dille, & McNair, 2008). Some authors argue that specialised training and qualifications are required to improve the performance of sonography (Goddi et al., 2012; Jeong et al., 2014). However our study indicates that novice operators within the constraints of the highly structured protocol of this study were as reliable as the experienced operator.

This study has several limitations. In relation to internal validity, the 95% CIs for all of the ICCs were wide, indicating a degree of uncertainty in the estimates of the ICCs. This could possibly relate to the small sample size used in our study. In relation to external validity, the participants of the present study were overall a young population. Muscle elasticity changes with age (Wang, Li, & Zheng, 2014) thus, the conclusions of the present study cannot be applied to the elderly population. Similarly, majority of the participants failed to meet the requirements for being considered ‘sufficiently active’ (Wanner et al., 2013). Physically active individuals are likely to be stronger than inactive individuals. Hence, these findings should not be generalized to athletic or physically active individuals, especially in light of

authors who have established differences in muscle stiffness in relation to muscle force (Bouillard et al., 2011).

Due to the exploratory nature of this study, several areas for future research have been identified. The reliability of UES at obtaining subcutaneous tissue, lateral gastrocnemius and soleus muscle stiffness needs further establishing with a larger sample size of both raters and participants. The next step would be to establish inter-session reliability and to begin to establish normative data on the stiffness of these tissues. The interval between sessions might usefully represent the interval between a treatment effect and follow-up session. Normative data based on large samples across wide age spectrum and physical activity levels would provide a baseline for future studies to use in the assessment of stiffness for the diagnosis of musculoskeletal dysfunction.

Information regarding the relationship between lower leg muscle stiffness may contribute to explaining epidemiological data regarding Achilles tendon and gastrocnemius tears. If UES is to be used in a clinical setting to monitor changes in muscle stiffness with treatment, it is important that the reliability of the measurement system is first determine.

In conclusion, this study demonstrates that the novice operators in this study were able to use UES within a session for the assessment the stiffness of the region of interest in the lower leg with acceptable reliability. The *intra*-operator reliabilities of the skilled and unskilled operators ranged from ‘high’ to ‘very high’, and the *inter*-operator reliability ranged from ‘trivial’ to ‘very high’. These findings provides a good rationale for a larger study involving a wide spectrum of participants and operators of varying levels of experience.

## REFERENCES

- Akagi, R., & Takahashi, H. (2013). Acute effect of static stretching on hardness of the gastrocnemius muscle. *Medicine and Science in Sports and Exercise*, *45*(7), 1348–1354.
- Badea, I., Tamas-Szora, A., Chiorean, I., Fildan, F., Ciuleanu, E., & Badea, M. (2014). Quantitative assessment of the masseter muscle's elasticity using Acoustic Radiation Force Impulse. *Medical Ultrasonography*, *16*(2), 89–94.
- Bamber, J., Cosgrove, D., Dietrich, C. F., Fromageau, J., Bojunga, J., Calliada, F., ... Piscaglia, F. (2013). EFSUMB guidelines and recommendations on the clinical use of ultrasound elastography. Part 1: Basic principles and technology. *Ultraschall in Der Medizin (Stuttgart, Germany : 1980)*, *34*(2), 169–84. doi:10.1055/s-0033-1335205
- Bentman, S., O'Sullivan, C., & Stokes, M. (2010). Thickness of the middle trapezius muscle measured by rehabilitative ultrasound imaging: description of the technique and reliability study. *Clinical Physiology & Functional Imaging*, *30*(6), 426–431. doi:10.1111/j.1475-097X.2010.00960.x
- Bota, S., Herkner, H., Sporea, I., Salzl, P., Sirli, R., Neghina, A. M., & Peck-Radosavljevic, M. (2013). Meta-analysis: ARFI elastography versus transient elastography for the evaluation of liver fibrosis. *Liver International*, *33*(8), 1138–47. doi:10.1111/liv.12240
- Botar-jid, C., Damian, L., Dudea, S. M., Vasilescu, D., & Rednic, S. (2010). The contribution of ultrasonography and sonoelastography in assessment of myositis. *Medical Ultrasonography*, *12*(2), 120–126.
- Botar-Jid, C., Damian, L., Dudea, S. M., Vasilescu, D., Rednic, S., & Radu Badea. (2010). The contribution of ultrasonography and sonoelastography in assessment of myositis. *Medical Ultrasonography*.
- Bouillard, K., Nordez, A., & Hug, F. (2011). Estimation of individual muscle force using elastography. *PloS One*, *6*(12), e29261. doi:10.1371/journal.pone.0029261
- Butler, J. V, Mulkerrin, E. C., & O'Keeffe, S. T. (2002). Nocturnal leg cramps in older people. *Postgraduate Medical Journal*, *78*(924), 596–598. doi:10.1136/pmj.78.924.596
- Campbell, J. T. (2009). Posterior calf injury. *Foot and Ankle Clinics*, *14*(4), 761–71. doi:10.1016/j.fcl.2009.07.005
- Chino, K., Akagi, R., Dohi, M., Fukushima, S., & Takahashi, H. (2012). Reliability and validity of quantifying absolute muscle hardness using ultrasound elastography. *PloS One*, *7*(9), e45764. doi:10.1371/journal.pone.0045764
- Chiou, H.-J., Chou, Y.-H., Chiou, S.-Y., Liu, J.-B., & Chang, C.-Y. (2003). Peripheral Nerve Lesions: Role of High-Resolution US. *Radiographics*, *23*(6). doi:10.1148/rg.e15

- Cho, K. H., & Nam, J. H. (2015). Evaluation of stiffness of the spastic lower extremity muscles in early spinal cord injury by acoustic radiation force impulse imaging. *Annals of Rehabilitation Medicine*, 39(3), 393–400. doi:10.5535/arm.2015.39.3.393
- Cohen, J. C. (2009). Anatomy and Biomechanical Aspects of the Gastrocnemius Complex. *Foot and Ankle Clinics*, 14(4), 617–626. doi:10.1016/j.fcl.2009.08.006
- Counsel, P., & Bredahl, W. (2010). Muscle injuries of the lower leg. *Seminars in Musculoskeletal Radiology*, 14(2), 162–75. doi:10.1055/s-0030-1253158
- Crommert, M. E., Lacourpaille, L., Heales, L. J., Tucker, K., & Hug, F. (2015). Massage induces an immediate, albeit short-term, reduction in muscle stiffness. *Scandinavian Journal of Medicine and Science in Sports*, 25(5), e490–e496. doi:10.1111/sms.12341
- Davies, E. L. (2014). *Reliability of crural fascia and Achilles tendon excursion using ultrasound imaging : A pilot study*. Masterthesis. Unitec Institute of Technology. Auckland, New Zealand.
- De Zordo, T., Chhem, R., Smekal, V., Feuchtner, G., Reindl, M., Fink, C., ... Klauser, a. S. (2010). Real-time sonoelastography: Findings in patients with symptomatic achilles tendons and comparison to healthy volunteers. *Ultraschall in Der Medizin*, 31(4), 394–400. doi:10.1055/s-0028-1109809
- DiGiovanni, C. W., Kuo, R., Tejawani, N., Price, R., Hansen, S. T., Cziernecki, J., & Sangeorzan, B. J. (2002). Isolated gastrocnemius tightness. *The Journal of Bone & Joint Surgery*, 84-A(August 2015).
- Dorado Cortez, C., Hermitte, L., Ramain, A., Mesmann, C., Lefort, T., & Pialat, J. B. (2015). Ultrasound shear wave velocity in skeletal muscle: A reproducibility study. *Diagnostic and Interventional Imaging*. doi:10.1016/j.diii.2015.05.010
- Drakonaki, E. E., & Allen, G. M. (2010). Magnetic resonance imaging, ultrasound and real-time ultrasound elastography of the thigh muscles in congenital muscle dystrophy. *Skeletal Radiology*, 39(4), 391–396. doi:10.1007/s00256-009-0861-0
- Drakonaki, E. E., Allen, G. M., & Wilson, D. J. (2012). Ultrasound elastography for musculoskeletal applications. *British Journal of Radiology*, 85(1019), 1435–1445. doi:10.1259/bjr/93042867
- Dubois, G., Kheireddine, W., Vergari, C., Bonneau, D., Thoreux, P., Rouch, P., ... Skalli, W. (2015). Reliable Protocol for Shear Wave Elastography of Lower Limb Muscles at Rest and During Passive Stretching. *Ultrasound in Medicine & Biology*, 1–8. doi:10.1016/j.ultrasmedbio.2015.04.020
- Ellis, R., Hing, W., Dille, A., & McNair, P. (2008). Reliability of Measuring Sciatic and Tibial Nerve Movement with Diagnostic Ultrasound During a Neural Mobilisation Technique. *Ultrasound in Medicine and Biology*, 34(8), 1209–1216. doi:10.1016/j.ultrasmedbio.2008.01.003
- Emery, A. E. H. (2002). The muscular dystrophies. *The Lancet*, 359, 687–695. doi:10.1016/S0140-6736(02)07815-7
- Ferreira, P. H., Ferreira, M. L., & Hodges, P. W. (2004). Changes in Recruitment of the Abdominal Muscles in People With Low Back Pain. *Spine*, 29(22), 2560–2566. doi:10.1097/01.brs.0000144410.89182.f9

- Fraquelli, M., Rigamonti, C., Casazza, G., Conte, D., Donato, M. F., Ronchi, G., & Colombo, M. (2007). Reproducibility of transient elastography in the evaluation of liver fibrosis in patients with chronic liver disease. *Gut*, *56*(7), 968–73. doi:10.1136/gut.2006.111302
- Gabbard, C., & Hart, S. (1996). A question of foot dominance. *The Journal of General Psychology*, *123*(4), 289–96. doi:10.1080/00221309.1996.9921281
- Gennisson, J.-L., Deffieux, T., Fink, M., & Tanter, M. (2013). Ultrasound elastography: Principles and techniques. *Diagnostic and Interventional Imaging*, (94), 487–495.
- Goddi, A., Bonardi, M., & Alessi, S. (2012). Breast elastography: A literature review. *Journal of Ultrasound*, *15*(3), 192–8. doi:10.1016/j.jus.2012.06.009
- Hopkins, W. G. (2000). Measures of Reliability in Sports Medicine and Science. *Sports Medicine*, *30*(1), 1–15. doi:10.2165/00007256-200030010-00001
- Jan Ekstrand, Martin Hägglund, & Markus Waldén. (2011). Epidemiology of Muscle Injuries in Professional Football ( Soccer ). *American Journal of Sports Medicine*, 1–7. doi:10.1177/0363546510395879
- Jeong, W. K., Lim, H. K., Lee, H.-K., Jo, J. M., & Kim, Y. (2014). Principles and clinical application of ultrasound elastography for diffuse liver disease. *Ultrasonography*, *33*(3), 149–160. doi:2014.33.3.149
- Kot, B. C. W., Zhang, Z. J., Lee, A. W. C., Leung, V. Y. F., & Fu, S. N. (2012). Elastic modulus of muscle and tendon with shear wave ultrasound elastography: variations with different technical settings. *PloS One*, *7*(8), e44348. doi:10.1371/journal.pone.0044348
- Krouskop, T. A., Wheeler, T. M., Kallel, F., Garra, B. S., & Hall, T. (1998). Elastic Moduli of Breast and Prostate Tissues under Compression. *Ultrasonic Imaging*, *20*(4), 260–274. doi:10.1177/016173469802000403
- Kuo, W.-H., Jian, D.-W., Wang, T.-G., & Wang, Y.-C. (2013). Neck muscle stiffness quantified by sonoelastography is correlated with body mass index and chronic neck pain symptoms. *Ultrasound in Medicine & Biology*, *39*(8), 1356–61. doi:10.1016/j.ultras medbio.2012.11.015
- Lacourpaille, L., Hug, F., Bouillard, K., Hogrel, J.-Y., & Nordez, A. (2012). Supersonic shear imaging provides a reliable measurement of resting muscle shear elastic modulus. *Physiological Measurement*, *33*(3), N19–N28. doi:10.1088/0967-3334/33/3/N19
- Lacourpaille, L., Hug, F., Guével, A., Péréon, Y., Magot, A., Hogrel, J.-Y., & Nordez, A. (2015). Non-invasive assessment of muscle stiffness in patients with Duchenne muscular dystrophy. *Muscle & Nerve*, *51*(2), 284–6. doi:10.1002/mus.24445
- Lacourpaille, L., Nordez, A., Hug, F., Couturier, A., Dibie, C., & Guilhem, G. (2014). Time-course effect of exercise-induced muscle damage on localized muscle mechanical properties assessed using elastography. *Acta Physiologica (Oxford, England)*, *211*(1), 135–46. doi:10.1111/apha.12272
- Li, Y., & Snedeker, J. G. (2011). Elastography: Modality-specific approaches, clinical applications, and research horizons. *Skeletal Radiology*, *40*(4), 389–397. doi:10.1007/s00256-010-0918-0

- Lucas, N., Macaskill, P., Irwig, L., Moran, R., & Bogduk, N. (2009). Reliability of physical examination for diagnosis of myofascial trigger points: a systematic review of the literature. *The Clinical Journal of Pain*, 25(1), 80–9. doi:10.1097/AJP.0b013e31817e13b6
- Lucas, N., Macaskill, P., Irwig, L., Moran, R., Rickards, L., Turner, R., & Bogduk, N. (2013). The reliability of a quality appraisal tool for studies of diagnostic reliability (QAREL). *BMC Medical Research Methodology*, 13, 111. doi:10.1186/1471-2288-13-111
- Lucas, N. P., Macaskill, P., Irwig, L., & Bogduk, N. (2010). The development of a quality appraisal tool for studies of diagnostic reliability (QAREL). *Journal of Clinical Epidemiology*, 63(8), 854–861. doi:10.1016/j.jclinepi.2009.10.002
- Luomala, T., Pihlman, M., Heiskanen, J., & Stecco, C. (2014). Case study: Could ultrasound and elastography visualized densified areas inside the deep fascia? *Journal of Bodywork and Movement Therapies*, 18(3), 462–468. doi:10.1016/j.jbmt.2013.11.020
- McCombe, D., Brown, T., Slavin, J., & Morrison, W. A. (2001). The histochemical structure of the deep fascia and its structural response to surgery. *Journal of Hand Surgery (British and European Volume)*, 26(2), 89–97. doi:10.1054/jhsb.2000.0546
- McKay, G. D., Goldie, P. a, Payne, W. R., & Oakes, B. W. (2001). Ankle injuries in basketball: injury rate and risk factors. *British Journal of Sports Medicine*, 35(2), 103–108. doi:10.1136/bjsm.35.2.103
- McKiernan, S., Chiarelli, P., & Warren-Forward, H. (2013). Professional issues in the use of diagnostic ultrasound biofeedback in physiotherapy of the female pelvic floor. *Radiography*, 19(2), 117–124. doi:10.1016/j.radi.2013.01.006
- Mueller-Wohlfahrt, H.-W., Haensel, L., Mithoefer, K., Ekstrand, J., English, B., McNally, S., ... Ueblacker, P. (2013). Terminology and classification of muscle injuries in sport: the Munich consensus statement. *British Journal of Sports Medicine*, 47(6), 342–50. doi:10.1136/bjsports-2012-091448
- Nightingale, K., Stutz, R., & Trahey, G. (2002). Acoustic Radiation Force Impulse Imaging of In Vivo Vastus Medialis Muscle. *Ultrasonic Imaging*, 24(2), 100–8. doi:10.1177/016173460202400203
- Potter, C. L., Cairns, M. C., & Stokes, M. (2012). Use of ultrasound imaging by physiotherapists: A pilot study to survey use, skills and training. *Manual Therapy*, 17(1), 39–46. doi:10.1016/j.math.2011.08.005
- Prateepavanich, P., Kupniratsaikul, V., & Charoensak, T. (1999). The relationship between myofascial trigger points of gastrocnemius muscle and nocturnal calf cramps. *Journal of the Medical Association of Thailand*, 82(5), 451–9.
- Sporea, I., Bota, S., Jurchis, A., Sirli, R., Grădinaru-Tascău, O., Popescu, A., ... Szilaski, M. (2013). Acoustic Radiation Force Impulse and Supersonic Shear Imaging Versus Transient Elastography for Liver Fibrosis Assessment. *Ultrasound in Medicine & Biology*, 39(11), 1933–1941. doi:10.1016/j.ultras medbio.2013.05.003
- Teyhen, D. S., Miltenberger, C. E., Deiters, H. M., Toro, Y. M. Del, Pulliam, J. N., Childs, J. D., ... Flynn, T. W. (2005). Abdominal Drawing-in Maneuver in. *Journal of Orthopaedic & Sports Physical Therapy*, 35(6), 346–355.

- Thompson, J. A., O'Sullivan, P. B., Briffa, N. K., & Neumann, P. (2006). Assessment of voluntary pelvic floor muscle contraction in continent and incontinent women using transperineal ultrasound, manual muscle testing and vaginal squeeze pressure measurements. *International Urogynecology Journal and Pelvic Floor Dysfunction*, *17*(6), 624–630. doi:10.1007/s00192-006-0081-2
- Turo, D., Otto, P., Hossain, M., Gebreab, T., Armstrong, K., Rosenberger, W. F., ... Sikdar, S. (2015). Novel Use of Ultrasound Elastography to Quantify Muscle Tissue Changes After Dry Needling of Myofascial Trigger Points in Patients With Chronic Myofascial Pain. *Journal of Ultrasound in Medicine*, *34*(12), 2149–61. doi:10.7863/ultra.14.08033
- Wang, C.-Z., Li, T.-J., & Zheng, Y.-P. (2014). Shear modulus estimation on vastus intermedius of elderly and young females over the entire range of isometric contraction. *PloS One*, *9*(7), e101769. doi:10.1371/journal.pone.0101769
- Wanner, M., Probst-Hensch, N., Kriemler, S., Meier, F., Bauman, A., & Martin, B. W. (2013). What physical activity surveillance needs: validity of a single-item questionnaire. *British Journal of Sports Medicine*. doi:10.1136/bjsports-2012-092122
- Yavuz, A., Bora, A., Bulut, M. D., Batur, A., Milanlioglu, A., Göya, C., & Andic, C. (2015). Acoustic Radiation Force Impulse (ARFI) elastography quantification of muscle stiffness over a course of gradual isometric contractions: A preliminary study. *Medical Ultrasonography*, *17*(1), 49–57. doi:10.11152/mu.2013.2066.171.yvz



## SECTION III – Appendices

## Appendix 1- Ethics documentation

Avish Sharma  
123d Dominion Road  
Mt Eden  
Auckland, 1024



18.6.15

Dear Avish,

Your file number for this application: 2015-1003

Title: Reliability of ultrasound imaging measures of soft tissue stiffness using elastography in the anterior thigh and posterior aspect of the leg.

Your application for amendments to the above ethics approval has been reviewed by the Unitec Research Ethics Committee (UREC) and has been approved for the following period:

Start date: 4.6.15

Finish date: 26.3.16

Please note that:

1. The above dates must be referred to on the information AND consent forms given to all participants.
2. You must inform UREC, in advance, of any ethically-relevant deviation in the project. This may require additional approval.

You may now commence your research according to the protocols approved by UREC.

We wish you every success with your project.

Yours sincerely,

A handwritten signature in blue ink, appearing to read 'PP Donaghey'.

Sara Donaghey  
Deputy Chair, UREC

cc: Rob Moran  
Cynthia Almeida

study@unitec.ac.nz  
Tel +64 9 849 4180  
Fax +64 9 815 2901  
www.unitec.ac.nz

Postal address  
Private Bag 92025  
Victoria St West  
Auckland 1142  
New Zealand

Mt Albert campus  
199 Carrington Rd  
Mt Albert  
Auckland 1025  
New Zealand

Newmarket campus  
277 Broadway  
Newmarket  
Auckland 1023  
New Zealand

Northern campus  
10 Rothwell Ave  
North Harbour  
Auckland 0632  
New Zealand

Waikare campus  
5-7 Rātanaui St  
Henderson  
Auckland 0612  
New Zealand



## Participant Consent Form

### **Reliability of ultrasound elastography imaging in the assessment of tissue stiffness of the anterior thigh compartment and the posterior leg compartment**

This research project is an investigation into the reliability of ultrasound elastography to assess the stiffness of the tissues of the anterior aspect of the thigh and the posterior aspect of the leg. This research is being undertaken by Master of Osteopathy students Avish Sharma and Paula Toledo, and will be supervised by Robert Moran and James Hutchinson.

I have had the research project explained to me and I have read and understand the information sheet given to me.

**I understand that I don't have to be part of this research project should I chose not to participate and may withdraw at any time until 24 hours following completion of data collection date.**

**I understand that everything I say is confidential and will be anonymized. That all of the information I give (consent forms) or is obtained from me (ultrasound imaging and questionnaires) will be anonymized. I also understand that all the raw data will be stored securely on a computer at Unitec for a period of 5 years before disposal.**

**I understand that I can see the finished research document.**

**I have had time to consider everything and I give my consent to be a part of this project.**

I know whom to contact if I have any questions or concerns about the project.

**The student researchers for this project are:**

Avish Sharma Tel: 021607471

Paula Toledo: Tel: 0221340611

Project email: elastographyresearch@gmail.com

**The project is supervised by Rob Moran:**

Tel: 021 073 9984      Email: rmoran@unitec.ac.nz

**Participant Name:** .....

**Participant Signature:** ..... **Date:**  
.....

**Project Researcher:** ..... **Date:**  
.....

**UREC REGISTRATION NUMBER: 2015-XXX**

This study has been approved by the UNITEC Research Ethics Committee from 26 March 2015 to 26 March 2016. If you have any complaints or reservations about the ethical conduct of this research, you may contact the Committee through the UREC Secretary (ph: 09 815-4321 ext 8551. Any issues you raise will be treated in confidence and investigated fully, and you will be informed of the outcome.



## Participant Information Sheet

### **Reliability of ultrasound elastography imaging in the assessment of tissue stiffness of the anterior thigh compartment and the posterior leg compartment**

#### **What does this research involve?**

You are invited to take part in a research project that aims to investigate the reliability or repeatability of ultrasound elastography imaging. Ultrasound elastography is a method to measure the stiffness or 'hardness' of muscles, tendons and other soft tissues. The parts of the body we are investigating are the front of the thigh and the calf area.

#### **What is elastography?**

Elastography is a helpful measurement technique that adds value to ultrasound imaging by enabling the assessment of 'stiffness' or 'hardness' of soft tissues. However, in the last few years there has been growing interest in the use of elastography for muscles, tendons and other soft-tissues for research purposes. Stiffness information may be useful in future studies investigating common therapies such as massage.

#### **What is interesting about elastography?**

Manual palpation has been a popular and successful method of assessing muscle stiffness for many years but is subject to differences between examiners. Elastography allows objective quantification of stiffness felt in tissues through manual palpation, this provides manual therapists an objective diagnostic tool and a research tool to provide insight into the biomechanics and pathophysiology of soft-tissues.

#### **Is there any risk related to receiving ultrasound elastography?**

Ultrasound imaging is widely accepted as a safe form of imaging. Ultrasound uses sound waves to create images of body tissues. This process generates a slight increase in tissue temperature, which

is a recognised and accepted effect of ultrasound. However, prolonged and uninterrupted exposure to extremely high sound frequencies may cause tissue damage from increased tissue temperature. The frequencies used in this study will be low and the time of exposure short. The protocol used in this study is well within the health safety standards stipulated by ISO 2012 framework 14971.

The ultrasound scans obtained from this study are for research purposes only and are not diagnostic of any particular health condition.

### **What will be required of me ?**

If you choose to participate you will need to undertake the following:

1. A brief telephone or personal conversation with one of the research team to screen for eligibility for the project. A full explanation of the study will be provided at this stage (10min). Confirmation of your eligibility to participate will occur at this stage. This conversation will take place within two days of expressing interest in the study
2. An information pack will be sent via email, including a general information sheet to be completed.
3. We would like you to have some time to think about any questions you may have and about your participation. You will receive a follow-up call to answer any questions relating to the study and to confirm your participation in the study.
4. You will need to sign the consent form before participation in the study can commence.
5. You will be required to attend a data collection session which will take approximately 60 minutes.

*The data collection date involves:*

1. Completing a disability questionnaire for the knee and ankle. These questionnaires are designed to assess each participant's level of leg disability (if any).
2. You will receive an ultrasound elastography scan on the front of your thigh and calf area by three different operators with different levels of experience (two beginners and an expert). Each operator will conduct the same ultrasound protocol, but you will have contact with only one operator at a time. The ultrasound protocol involves the operator placing a gel substance on each participant's (front) thigh and calf; this helps with the ultrasound image visualization. An ultrasound probe will be placed on the front of your thigh and on your calf for measurements to be taken.
3. The total ultrasound time is scheduled to be one hour, approximately 20 minutes per operator.

**Do I have to avoid any activity before data collection?**

Participants are asked not to exercise on the day of the data collection. This helps us control for any effect exercise can have on soft tissues (muscles, fascia, tendon, etc.). Exercise can warm-up the soft tissues, and decreasing stiffness in the muscles by increasing muscle temperature.

**What do I need to bring on the day of the data collection session?**

You don't need to bring anything, if you want you can bring your own pair of shorts, however shorts will be available for you to borrow.

**Will I be able to withdraw whenever I want to?**

Yes, you have the right to not participate, or to withdraw from this research project at any time until 24 hours following the data collection. This can be done by phone, email or in person.

**Will I receive further information on the progress of the study and results?**

Yes, you will be asked by one of the researchers whether you want to receive this information. If you wish we will send a brief email with a summary of the updated information on the progress of this study. You also have the right to access the data collected from your leg upon request. This information can also be sent to you by email. The study may also be published after it is submitted and marked. You will be asked if you would like to receive an electronic copy of the published study.

**Will the information taken throughout the study be confidential?**

We will ensure that the information you have given us is kept completely confidential. All the data collected from our participants during the study will be anonymized and will be stored securely on a password protected file so that only the two principal researchers and our supervisors can access. Raw data will be stored for five years following the study and will then be destroyed.

**What are the possible outputs from the project?**

The study may be published after it is submitted and marked. Also the abstract of the study may be presented at conferences.

**Consent**

This information will be revised with you in person before the commencement of the study. This will give you the opportunity for you to clear any doubts or concerns. Both verbal and written consent will be gained from you and it is taken as an indication that you consent to participate in this study. As mentioned before, this consent does not stop you from changing your mind if you wish to withdraw from the project.

**Who can I contact for further information, concerns or queries?**

Please feel free to contact us at any time if you have any concerns, queries or require any further information about the research project.

*Student researchers:*

**Avish Sharma**

Tel: 0211607471

**Paula Toledo**

Tel: 0221340611

Email: elastographyresearch@gmail.com

*Research Supervisors:*

**Rob Moran**

Tel: 021 073 9984 or 09 815 4321 ext 8197

Email: rmoran@unitec.ac.nz

**James Hutchinson**

Tel: 027 3498919 or 09 815 4321 ext 7914

Email: jhutchinson@unitec.ac.nz

*Thank you very much for your participation. If you have any questions at any time during the course of the study or following the completion of the study, please don't hesitate to contact us.*

**UREC REGISTRATION NUMBER: 2015-1003**

**This study has been approved by the UNITEC Research Ethics Committee from 26 March 2015 to 26 March 2016. If you have any complaints or reservations about the ethical conduct of this research, you may contact the Committee through the UREC Secretary (ph: 09 815-4321 ext 8551. Any issues you raise will be treated in confidence and investigated fully, and you will be informed of the outcome.**